


## BRIEF COMMUNICATION

# Vertebral artery dissection associated with familial Mediterranean fever and Behçet's disease

Hidehiro Ishikawa<sup>1</sup> , Akihiro Shindo<sup>1</sup>, Yuichiro Ii<sup>1</sup>, Shoko Sakano<sup>1</sup>, Masaru Asahi<sup>1</sup>, Keita Matsuura<sup>1</sup>, Dai Kishida<sup>2</sup>, Maki Umino<sup>3</sup>, Masayuki Maeda<sup>4</sup> & Hidekazu Tomimoto<sup>1</sup>

<sup>1</sup>Department of Neurology, Mie University Graduate School of Medicine, Tsu, Mie, Japan

<sup>2</sup>Department of Medicine (Neurology and Rheumatology), Shinshu University School of Medicine, Nagano, Japan

<sup>3</sup>Department of Radiology, Mie University Graduate School of Medicine, Tsu, Mie, Japan

<sup>4</sup>Department of Advanced Diagnostic Imaging, Mie University Graduate School of Medicine, Tsu, Mie, Japan

## Correspondence

Hidehiro Ishikawa, 2-174 Edobashi Tsu city, Mie 514-8507, Japan. Tel: +81 59 232 1111; Fax: +81 59 231 5541; E-mail: hidehiro-i@clin.medic.mie-u.ac.jp

## Funding Information

This work was supported by JSPS KAKENHI (grant number 18K15446).

Received: 22 January 2019; Revised: 9 March 2019; Accepted: 13 March 2019

*Annals of Clinical and Translational Neurology* 2019; 6(5): 974–978

doi: 10.1002/acn3.773

## Introduction

Behçet's disease (BD) affects multiple parts of the body, including the eyes, skin, mucosa, joints, vascular system, lungs, and nervous system. BD rarely causes recurrent aseptic meningitis,<sup>1</sup> or vertebral artery dissection (VAD).<sup>2</sup> Familial Mediterranean fever (FMF) is associated with BD<sup>3</sup> and also rarely occurs with recurrent aseptic meningitis.<sup>4</sup> Here, we describe a patient with atypical BD who exhibited recurrent aseptic meningitis and VAD. Moreover, she exhibited three heterozygous mutations in the familial Mediterranean fever (*MEFV*) gene and fulfilled the diagnostic criteria for diagnosis of FMF.

## Case Presentation

A 52-year-old woman presented with a severe headache. Her family history was unremarkable. She had a history of recurrent oral ulcer, occasional joint pain, and eight episodes of aseptic meningitis beginning at 20 years of age. Screening tests for infection, malignancy, and autoimmune causes were performed during each hospitalization; all were negative. The prior episode of meningitis

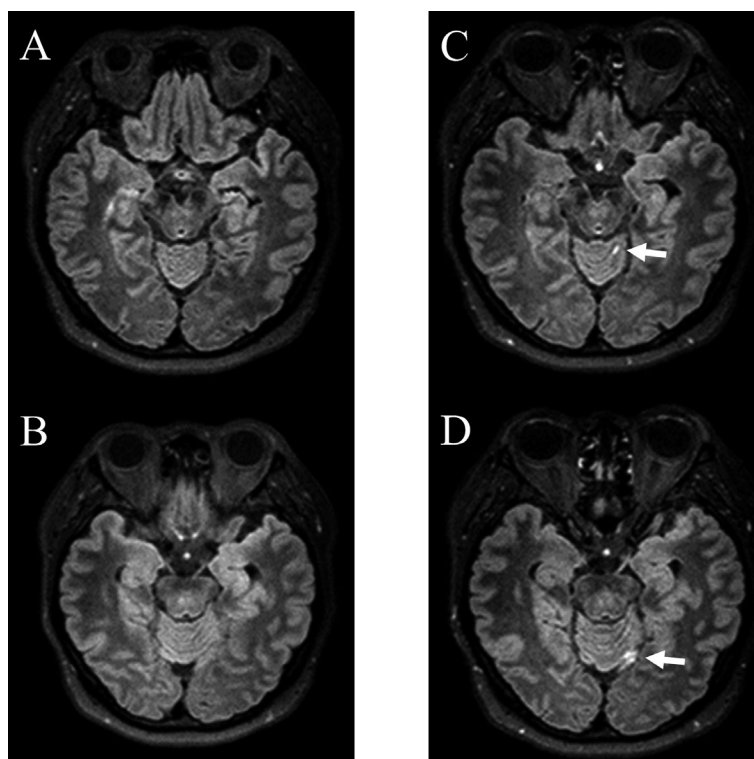
## Abstract

Vertebral artery dissection and recurrent meningitis are rare complications in Behçet's disease. Behçet's disease may be associated with familial Mediterranean fever. Here, we describe a 52-year-old woman with severe headache who exhibited recurrent meningitis and vertebral artery dissection. Cerebrospinal fluid showed high levels of interleukin-6. Magnetic resonance imaging revealed right vertebral artery dissection. The patient had three heterozygous mutations in the familial Mediterranean fever gene (*MEFV*) gene. She fulfilled criteria for diagnosis of Behçet's disease and familial Mediterranean fever. In conclusion, mutations of the *MEFV* gene may cause neuro-inflammatory disorders and cerebrovascular disorders by reducing anti-inflammatory activity of pyrin.

was treated at our hospital, when the patient was 48 years of age. At that time, her body temperature was 37.2°C; serum C-reactive protein (CRP), 0.55 mg/dL; and erythrocyte sedimentation rate (ESR), 8 mm/h. Cerebrospinal fluid (CSF) showed 225 cells/mm<sup>3</sup> (mononuclear cells > 99%), 62 mg/dL protein, 51 mg/dL glucose (93 mg/dL serum glucose), and 305 pg/mL interleukin (IL)-6 on chemiluminescent enzyme immunoassay analysis. Brain magnetic resonance imaging (MRI) revealed high-intensity lesions along the brain groove of the cerebellum in three-dimensional fluid-attenuated inversion recovery (3D FLAIR), which was consistent with a diagnosis of mild meningitis<sup>5</sup> (Fig. 1). Her pathergy test was positive and diagnosed with BD based on the international criteria for BD.<sup>6</sup> Human leucocyte antigen (HLA) typing revealed negative for B51 and positive for B15.

The patient's condition improved after treatment with colchicine (1 mg daily) and she had stopped medication without medical input at 51 years of age.

During the present episode, she complained of headache similar to that in prior episodes of meningitis, and her neurological examination was normal except for the presence of stiff neck and jolt accentuation. Her body



**Figure 1.** Magnetic resonance imaging during hospitalization due to meningitis. Three-dimensional fluid-attenuated inversion recovery (3D FLAIR; axial, 3T; retention time 6000 msec, echo time 367 msec) was normal (A, B). Postcontrast 3D FLAIR revealed high-intensity lesions along the brain groove of the cerebellum, which suggested meningitis (C, D).

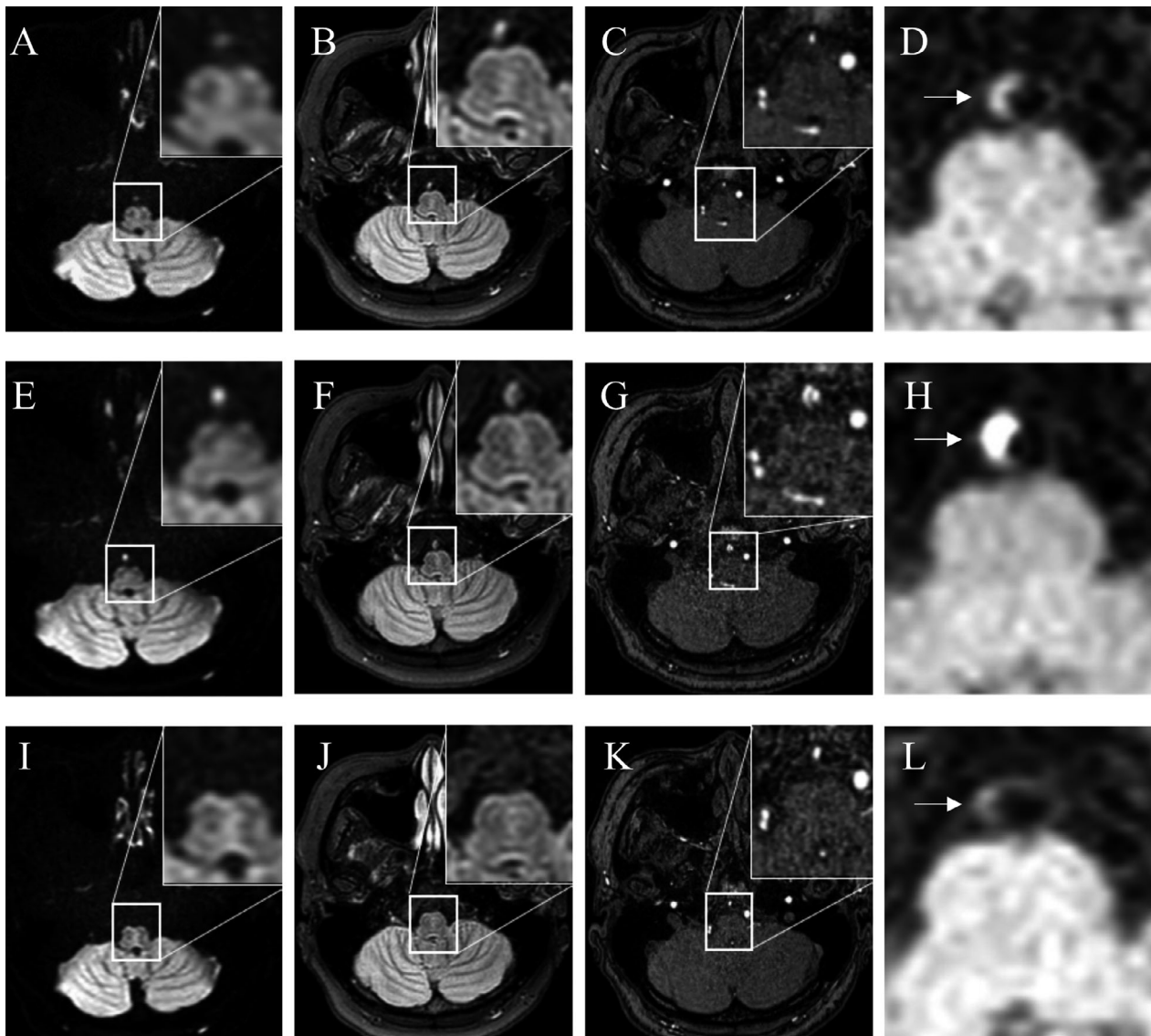
temperature was 36.9°C; serum CRP, 0.23 mg/dL; and ESR, 9 mm/h. CSF findings included normal cell counts, normal protein level, and elevated IL-6 (35 pg/mL). Brain MRI revealed narrowing of the vertebral artery (VA) and dot-shaped high-intensity findings in the right VA on diffusion-weighted imaging (DWI) and 3D FLAIR (Fig. 2A–D). One week later, the lesion was confirmed as VAD (Fig. 2E–H). The patient's headache gradually improved after she restarted intake of colchicine (1 mg, daily). Because she had also experienced occasional fever and exertional leg pain, genetic analysis of *MEFV* was conducted. Five mutation hot spot regions, exons 1, 2, 3, 5, and 10 of the *MEFV* gene, were analyzed using polymerase chain reaction.<sup>7</sup> This analysis revealed E148Q in exon 2, as well as P369S and P408Q in exon 3 (Fig. 3). The patient was diagnosed with FMF based on the established diagnostic criteria.<sup>8</sup> The intramural hematoma diminished 4 months later (Fig. 2I–L).

## Discussion

This case demonstrates two important clinical issues. First, a patient with BD showed two rarely identified neurological involvements (recurrent aseptic meningitis and

VAD), which were concurrent. Second, the patient exhibited three mutations in the *MEFV* gene.

Both BD and FMF share common symptoms such as fever, arthritis, and abdominal pain; moreover, a high prevalence of FMF has been reported among patients with BD.<sup>3</sup> Notably, VAD and aseptic meningitis constitute rare nervous system manifestations in patients with BD. Moreover, headache is a common symptom in patients with VAD and meningitis. It might be difficult to distinguish between VAD and meningitis, because these are rarely involved in BD. Although the headache was thought to be nonspecific and related to neuro-BD, rather than meningitis after lumbar puncture, MRI findings supported a diagnosis of VAD. Hyperintense signal in the VA on DWI, 2 weeks from the onset of headache suggested VAD.<sup>9</sup> The movement of water molecules may be restricted within the intramural hematoma on arterial dissection. High intensity or iso-intensity in the VA on 3D FLAIR may represent intramural hematoma or thrombus because vascular hyper-intensities associated with vessel occlusion or stenosis are not visible on 3D FLAIR.<sup>10</sup> Clinicians should closely monitor high-intensity dot signals on DWI, in addition to FLAIR, which may suggest the existence of VAD. VA dot signs in patients with



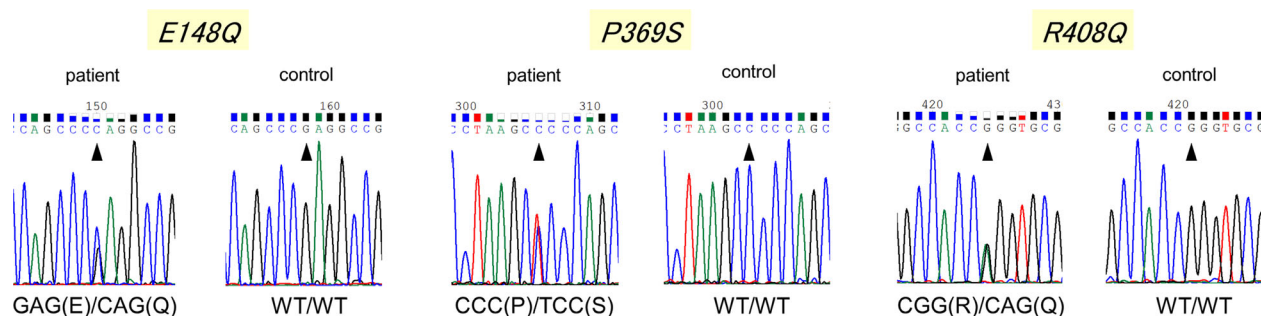
**Figure 2.** Magnetic resonance imaging (MRI) on admission (A–D). Diffusion-weighted imaging (DWI) showed isointense dot signals in the right vertebral artery (VA) (A). Three-dimensional fluid-attenuated inversion recovery (3D FLAIR) showed high-intensity signals (B). Magnetic resonance angiography (MRA) showed narrowing of the VA (C). Black-blood T1-weighted imaging (T1WI) revealed a slight high-intensity area in VA (D). MRI at 10 days after admission (E–H). DWI showed that the lesion exhibited high intensity (E), whereas the FLAIR lesion became isointense (F). The right VA showed a double lumen on MRA (G); intramural hematoma was confirmed on T1WI (H). MRI at 4 months after admission (I–L). Right VA signals disappeared on DWI (I) and FLAIR (J). Stenosis on MRA (K) and slight high intensity in the right VA remained on T1WI (L).

headaches may be critical in determining the presence of VAD, even in rare cases. Further studies are needed to elucidate the pathogenic mechanisms underlying signals in VA on DWI and FLAIR in VAD patients, as well as the changes in the signal intensities.

The patient's spontaneous VAD was likely caused by the complex factors of BD, FMF, and meningitis. VAD can arise in patients with BD,<sup>11</sup> whereas FMF change cerebral blood flow in a manner that increases risk of VD.<sup>12</sup> Furthermore, meningitis can increase risk of VAD

because inflammation-associated injury of the arterial wall can cause weakness of the vessel wall and subsequent dissection.<sup>13,14</sup> The prior episode of meningitis in our patient may have occurred near the posterior circulation (Fig. 1).

This patient had three *MEFV* gene mutations. P369S and P408Q mutations are associated with a variety of phenotypes and are not commonly associated with classical FMF symptoms.<sup>15</sup> Recently, we reported that *MEFV* mutations were detected in neuro-Sweet disease.<sup>16</sup> Both



**Figure 3.** Genetic analysis of *MEFV* depicting heterozygous mutations in exon 2 (E148Q) and 3 (P369S and P408Q).

neuro-BD and neuro-Sweet disease overlap with each other.<sup>17</sup> Our patient exhibited recurrent meningitis and VAD in the context of atypical BD, and had three heterozygous mutations (E148Q, P369S, and P408Q) in the *MEFV* gene. The *MEFV* gene encodes for the pyrin protein, which has been hypothesized to suppress the activation of pro-caspase-1; thus, it is suspected to interfere with inflammasome activation.<sup>8</sup> Although some inflammasomes have been revealed to have important roles in atherosclerosis and neurological disorders, including meningitis and stroke,<sup>18,19</sup> associations between the pyrin inflammasome and neurological manifestations have not been elucidated.<sup>20</sup> We speculate that autoinflammation might be common to BD and FMF, and that it causes both neuro-inflammatory symptoms and cerebrovascular disorders. Patients with BD who exhibit rare neurological manifestations may have mutations in the *MEFV* gene.

## Acknowledgment

This work was supported by JSPS KAKENHI (grant number 18K15446).

## Author Contribution

HI contributed to interpretation of the findings, wrote the initial draft of the report and revised and edited the manuscript. YI, SS, MA and KM were involved in treatment planning and revised and edited the manuscript. DK was involved in *MEFV* gene analysis and edited the manuscript. MU and MM were involved in acquisition and interpretation of radiological findings and drafting and revising the manuscript. AS and HT were involved in treatment planning, contributed to interpretation of the findings and critical revision of the manuscript.

## Conflicts of Interest

The authors declare that they have no conflict of interest.

## Ethical Standards

For this type of study, formal consent is not required because it is a case report, so every diagnostic test and treatments were performed according to the clinical practice.

## Informed Consent

Informed consent for publication of the case report anonymously, was obtained from the patient.

## Reference

1. Fonseca Cardoso A, Rocha-Filho PA, Melo Correa-Lima AR. Neuro-Behcet: differential diagnosis of recurrent meningitis. *Rev Med Chil* 2013;141:114–118.
2. Akman-Demir G, Serdaroglu P, Tasci B. Clinical patterns of neurological involvement in Behcet's disease: evaluation of 200 patients. The Neuro-Behcet Study Group. *Brain* 1999;122(Pt 11):2171–2182.
3. Watad A, Tiosano S, Yahav D, et al. Behcet's disease and familial Mediterranean fever: two sides of the same coin or just an association? A cross-sectional study. *Eur J Intern Med* 2017;39:75–78.
4. Yusef D, Khasawneh W. Familial mediterranean fever presenting with recurrent aseptic meningitis: a case report. *Pediatr Neonatol* 2017;58:378–379.
5. Lee JS, Park JK, Kim SH, et al. Usefulness of contrast enhanced FLAIR imaging for predicting the severity of meningitis. *J Neurol* 2014;261:817–822.
6. International Team for the Revision of the International Criteria for Behçet's Disease (ITR-ICBD). The International Criteria for Behçet's Disease (ICBD): a collaborative study of 27 countries on the sensitivity and specificity of the new criteria. *J Eur Acad Dermatol Venereol* 2014;28:338–347.
7. Kishida D, Nakamura A, Yazaki M, et al. Genotype-phenotype correlation in Japanese patients with familial Mediterranean fever: differences in genotype and clinical features between Japanese and Mediterranean populations. *Arthritis Res Ther* 2014;16:439.

8. Alghamdi M. Familial mediterranean fever, review of the literature. *Clin Rheumatol* 2017;36:1707–1713.
9. Choi KD, Jo JW, Park KP, et al. Diffusion-weighted imaging of intramural hematoma in vertebral artery dissection. *J Neurol Sci* 2007;253(1–2):81–84.
10. Hodel J, Leclerc X, Rodallec M, et al. Fluid-attenuated inversion recovery vascular hyperintensities are not visible using 3D CUBE FLAIR sequence. *Eur Radiol* 2013;23:1963–1969.
11. Bahar S, Coban O, Gurvit IH, et al. Spontaneous dissection of the extracranial vertebral artery with spinal subarachnoid haemorrhage in a patient with Behcet's disease. *Neuroradiology* 1993;35:352–354.
12. Cetin G, Utku U, Atilla N, et al. Changes in cerebral blood flow in patients with familial mediterranean fever. *Noro Psikiyatrs Ars* 2017;54:105–107.
13. Pan X, Ma A, Wang K, et al. Vertebral artery dissection associated with viral meningitis. *BMC Neurol* 2012;22:79.
14. Pelz JO, Harms K, Metze M, Michalski D. Spontaneous cervical artery dissection is accompanied by a hypercoagulable state and simultaneous inflammatory condition. *J Neurol* 2018;265:308–314.
15. Ryan JG, Masters SL, Booty MG, et al. Clinical features and functional significance of the P369S/R408Q variant in pyrin, the familial Mediterranean fever protein. *Ann Rheum Dis* 2010;69:1383–1388.
16. Ishikawa H, Shindo A, Ii Y, et al. Mediterranean fever gene mutations in patients with possible neuro-Sweet disease: a case series. *J Neurol Neurosurg Psychiatry* 2018;89:1119–1121.
17. Hisanaga K. Neuro-neutrophilic disease: neuro-behçet disease and neuro-sweet disease. *Intern Med* 2007;46:153–154.
18. Mamik MK, Power C. Inflammasomes in neurological diseases: emerging pathogenic and therapeutic concepts. *Brain* 2017;140:2273–2285.
19. Grebe A, Hoss F, Latz E. NLRP3 Inflammasome and the IL-1 Pathway in Atherosclerosis. *Circ Res* 2018;122:1722–1740.
20. Heilig R, Broz P. Function and mechanism of the pyrin inflammasome. *Eur J Immunol* 2018;48:230–238.