

Technical Note

Usefulness of needle holder with a function of fine forceps for bypass surgery in both hands

Tetsuyoshi Horiuchi, Tatsuya Seguchi¹, Kiyoshi Ito, Kazuhiro Hongo

Departments of Neurosurgery, Shinshu University School of Medicine, Matsumoto, Japan, ¹Seguchi Neurosurgical Hospital, Iida, Japan

E-mail: *Tetsuyoshi Horiuchi - tetuyosi@shinshu-u.ac.jp; Tatsuya Seguchi - tseguchi@mac.com; Kiyoshi Ito - kitoh@shinshu-u.ac.jp;

Kazuhiro Hongo - khongo@shinshu-u.ac.jp

*Corresponding author

Received: 02 December 14 Accepted: 18 December 14 Published: 02 April 15

This article may be cited as:

Horiuchi T, Seguchi T, Ito K, Hongo K. Usefulness of needle holder with a function of fine forceps for bypass surgery in both hands. *Surg Neurol Int* 2015;6:55.
Available FREE in open access from: <http://www.surgicalneurologyint.com/text.asp?2015/6/1/55/154464>

Copyright: © 2015 Horiuchi T. This is an open-access article distributed under the terms of the Creative Commons Attribution License, which permits unrestricted use, distribution, and reproduction in any medium, provided the original author and source are credited.

Abstract

Background: In bypass surgery, a single-handed needle holder is usually used with other handed fine forceps. Recently, a needle holder with the function of fine forceps has been developed.

Methods: In this technical note, usefulness of newly developed needle holders in both hands is presented in bypass surgery.

Results: With this method, surgeons can make stitches and ties by both hands without exchanging instruments.

Conclusions: This method is effective and may result in faster anastomotic procedure comparing with the traditional one.

Key Words: Anastomosis, bypass, forceps, needle holder, surgery

Access this article online

Website:

www.surgicalneurologyint.com

DOI:

10.4103/2152-7806.154464

Quick Response Code:



INTRODUCTION

Extracranial-intracranial (EC-IC) bypass surgery such as superficial temporal artery-middle cerebral artery (STA-MCA) bypass has been widely performed for moyamoya disease, artery involved tumors, complex aneurysms, and selected ischemic stroke due to arteriosclerosis.^[1-8] The success of bypass surgery depends upon meticulous technique and the use of appropriate instruments.^[1-3,8] Usually, needle holder in dominant hand and fine forceps as holding tissue in nondominant hand have been widely used during making stitches between donor and recipient [Figure 1a]. Then, both-handed fine forceps are commonly used when tying the suture. Because it is difficult to hold nylon threads using conventional needle holders [Figure 1a]. By contrast, fine forceps is not good for handling the needle. In this technical note, we propose the usage of both-handed needle holders with a function of fine forceps [Figure 1b] in EC-IC bypass.

DESCRIPTION OF THE TECHNIQUE

STA-MCA bypass is carried out in the standard manner^[2,4,7] with newly developed needle holder [Figures 2 and 3] usage as described below. No surgical complications related to the needle holder have been observed in our experience.

A new type of needle holder having fine long jaws as acting fine forceps is recently released from Mizuho Co., Ltd., Tokyo, Japan and Muranaka Medical Instruments Co., Ltd., Osaka, Japan [Figures 2 and 3]. Although both needle holders have a function of fine forceps, there is a difference in the handles. A round handle is made by Mizuho and a flat handle by Muranaka [Figure 2]. The present needle holders easily hold the 10-0 and 11-0 monofilament nylons [Figure 1d]. The tips of the present needle holder can be placed into the vessel lumen [Figure 1c]. If a surgeon has the present needle

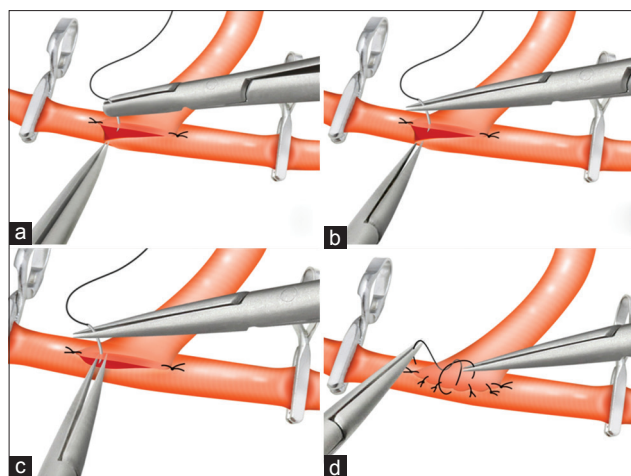


Figure 1: Illustrations of a new anastomotic method using both-handed needle holder with a function of fine forceps. (a) Traditional method using a needle holder in the dominant hand and a fine forceps in the nondominant hand. (b) The present method using both-handed newly developed needle holder. The present needle holder in the left hand can hold the adventitia of the vessel. (c) The tips of the present needle holder on the left are placed into the vessel lumen and the right needle holder thrusts the needle through the vessel wall between the left-sided tips which provide counter pressure. (d) Tying procedure the suture with both-handed needle holders

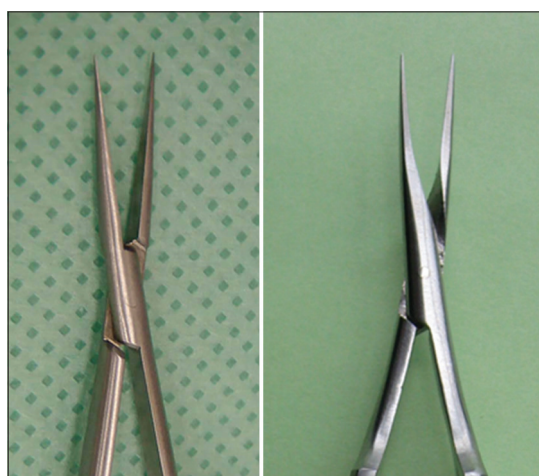

Figure 3: Close-up of the tips of Mizuho (left) and Muranaka (right) needle holders

holders in both hands to perform bypass surgery, no exchanging of the instruments is necessary to make stitches and tie threads [Figure 1d]. A surgeon also makes stitches in nondominant hand.

DISCUSSION

Although several surgical techniques are available such as double insurance bypass,^[5] the fingertip support technique,^[3] and mattress anastomosis,^[1] good micro-instruments are mandatory for accurately performing high quality bypass surgery. In this technical note, we present a new micro-needle holder in both hands that offers good handles of needle and threads.

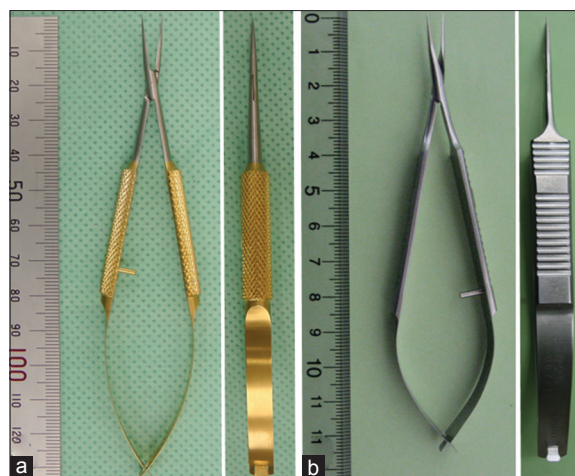


Figure 2: Overview of the new needle holder. Left (a) Fine jaws with round handle produced Mizuho. Right (b) Fine jaws with flat handle produced by Muranaka

The present needle holder allows a surgeon an excellent handling such as placing tips into the vessel lumen for counter-pressure [Figure 1c] when the needle is passed through the wall and lightly grasping the adventitia [Figure 1b] including making stitches. Since the novice neurosurgeons have difficulty to place tips into the vessel lumen and apply counter-pressure using fine forceps, they should practice to learn accurate skilled movements using fine forceps such as jeweler's forceps. In contrast to the process of learning to operate on with fine forceps, the newly developed needle holder usage can be easy to perform the appropriate bypass.

The fine forceps sometimes damage or snap monofilament nylons during tying threads because the tips of forceps are too sharp and hold nylons in a pin-point manner. By contrast, the present smooth needle folder jaw with rounded edges rarely damage monofilament sutures. This is also an advantage of a both-handed needle holder technique.

In our experience, only the present needle holder usage without fine forceps is difficult in very small recipient bypass (less than 0.7 mm in size) in some patients with moyamoya disease. Therefore, such extremely fragile vessel bypass still requires the ultra-fine forceps.

CONCLUSION

This technique can facilitate faster and more efficient microsurgical anastomosis, which the novice neurosurgeon may find useful. The present needle holder in both hands might reduce the occlusion time without exchanging the instruments.

REFERENCES

1. Aihara M, Fujimaki H, Shintoku R, Osawa T, Asakura K, Miyazaki M, et al. Mattress anastomosis in micro vascular reconstruction: Technical note. *Acta*

- Neurochir (Wien) 2013;155:607-9.
2. Charbel FT, Meglio G, Amin-Hanjani S. Superficial temporal artery-to-middle cerebral artery bypass. *Neurosurgery* 2005;56:186-90.
 3. Csokay A, Imreh D, Papp A, Valalik I. Straight needle with fingertip support technique reduces exclusion time during bypass (*in vitro, in vivo* animal study): A technical note. *Acta Neurochir (Wien)* 2012;154:1851-4.
 4. Gross BA, Du R. STA-MCA bypass. *Acta Neurochir (Wien)* 2012;154:1463-7.
 5. Hongo K, Horiuchi T, Nitta J, Tanaka Y, Tada T, Kobayashi S. Double-insurance bypass for internal carotid artery aneurysm surgery. *Neurosurgery* 2003;52:597-602.
 6. Horiuchi T, Kusano Y, Asanuma M, Hongo K. Posterior auricular artery-middle cerebral artery bypass for additional surgery of moyamoya disease. *Acta Neurochir (Wien)* 2012;154:455-6.
 7. Horiuchi T, Nitta T, Ishizaka S, Kanaya K, Yanagawa T, Hongo K. Emergency EC-IC bypass for symptomatic atherosclerotic ischemic stroke. *Neurosurg Rev* 2013;36:559-65.
 8. Horiuchi T, Tsutsumi K, Hasegawa T, Hongo K. Rescue revision techniques for end-to-side anastomosis. Technical note. *Surg Neurol Int* 2014;5:94.