

## ORIGINAL ARTICLE

# McGRATH MAC video laryngoscope for insertion of a transoesophageal echocardiography probe

## *A randomised controlled trial*

Takashi Ishida, Chiaki Kiuchi, Takemi Sekiguchi, Takatoshi Tsujimoto and Mikito Kawamata

**BACKGROUND** Transoesophageal echocardiography (TOE) probe insertion in anaesthetised patients can cause pharyngeal and oesophageal injuries. Kim *et al.* have shown that insertion assisted by a Macintosh laryngoscope can reduce such complications but it may sometimes be difficult to observe the passage of a TOE probe. The McGRATH MAC (McGRATH) has been shown to provide a better view of the glottis, piriform fossa and oesophageal inlet during tracheal intubation than the Macintosh.

**OBJECTIVE** We hypothesised that the McGRATH provided better visualisation of the oesophageal inlet and was useful as an aid to TOE probe placement, possibly reducing the incidence of pharyngeal injury related to insertion, compared with the Macintosh.

**DESIGN** A randomised controlled trial.

**SETTING** The study was conducted in a university hospital from February to December 2014.

**PATIENTS** One hundred patients undergoing elective surgery under intraoperative TOE monitoring were randomised to either a Macintosh group or a McGRATH group.

**INTERVENTIONS** Macintosh and McGRATH were used to visualise the passage of the TOE probe and guide its insertion.

**MAIN OUTCOME MEASURES** Visibility of the oesophageal inlet, the number of TOE insertion attempts and incidence of pharyngeal mucosal injury after the TOE probe had been removed were assessed.

**RESULTS** The percentage of patients in whom the oesophageal inlet was visible was higher in the McGRATH group (88%) than in the Macintosh group (41%) ( $P < 0.01$ ). The number of TOE probe insertion attempts was significantly smaller in the McGRATH group than in the Macintosh group ( $P = 0.039$ ). The incidence of pharyngeal mucosal injury was significantly smaller in the McGRATH group (4%) than in the Macintosh group (16%;  $P = 0.042$ ).

**CONCLUSION** The McGRATH provided a better view of the oesophageal inlet and was useful as an aid to TOE probe placement, possibly reducing the incidence of pharyngeal injury related to its insertion.

**TRIAL REGISTRATION** University Hospital Medical Information Network in Japan (UMIN) 000012970.

Published online 14 November 2015

## Introduction

Although transoesophageal echocardiography (TOE) is considered a well tolerated technique, rare but serious complications have been reported.<sup>1–6</sup> In anaesthetised patients, the total incidence of oropharyngeal injury associated with insertion of a TOE probe ranges from 0.2 to 1.2%,<sup>1,3,5</sup> and oesophageal perforation, the most feared complication, occurs in 0.01 to 0.09% of both ambulatory and anaesthetised patients.<sup>1–4</sup> When

oesophageal perforation occurs, it most commonly affects the hypopharynx and the oesophagus, the incidence of which are 0.01 and 0.02%, respectively.<sup>2,4,7–9</sup> Oesophageal perforation occurs more frequently in the upper oesophagus including the oesophageal inlet than in the middle to lower oesophagus,<sup>1,2,4</sup> similar to that after endoscopic fibroscope insertion.<sup>4</sup> This is probably because the crossing of fibres from the constrictor muscle

From the Department of Anaesthesiology and Resuscitation, Shinshu University School of Medicine, Matsumoto, Japan

Correspondence to Takashi Ishida, MD, Department of Anaesthesiology and Resuscitation, Shinshu University School of Medicine, 3-1-1, Asahi, Matsumoto, Nagano 390-8621, Japan

Tel: +812 6337 2670; fax: +812 6335 2734; e-mail: tisd@shinshu-u.ac.jp

of the pharynx and the cricopharyngeus muscle make this portion of the oesophagus particularly susceptible to injury and perforation.<sup>4</sup>

The incidence of minor adverse effects related to TOE probe insertion such as oropharyngeal mucosal injury seems to be more frequent in anaesthetised patients, but data is lacking and there is just a single study that puts the incidence of mucosal injury after blind TOE probe insertion at 55%, a relatively high figure.<sup>10</sup>

Perforation of the hypopharynx and upper oesophagus after TOE probe insertion is likely to be caused by difficulties introducing the probe into the inlet of the oesophagus, generating undue pressure at the tip of the probe. Mucosal injury in the pharynx and oesophageal inlet *per se* is not serious but would also result from excessive pressure exerted by the probe tip. Prevention of these complications requires that force during insertion is avoided, and for this, direct visualisation of the inlet of the oesophagus is desirable. Insertion under direct vision with a Macintosh laryngoscope (Macintosh) can reduce the high incidence of oropharyngeal injury from 55 to 5%.<sup>10</sup> The presence of an endotracheal tube prevents direct visualisation of the oesophageal inlet even when using the Macintosh, and it may sometimes be difficult to observe the passage of a TOE probe, creating conditions for pharyngeal injury.

The McGRATH MAC (McGRATH; Aircraft Medical Ltd., Edinburgh, UK) is a recently developed video laryngoscope that provides a better view of the glottis, piriform fossa and oesophageal inlet in tracheal intubation than the Macintosh.<sup>11,12</sup> We hypothesised that the McGRATH would provide better visualisation of the oesophageal inlet and would reduce the incidence of pharyngeal injury related to insertion of a TOE probe. The aim of this study was to evaluate the usefulness of the McGRATH as an aid to TOE probe placement compared with the Macintosh.

## Materials and methods

The study protocol was approved by the Institutional Ethics Committee of Shinshu University School of Medicine, Matsumoto, Japan (document no.: 2206) on 5 February 2013. It was then registered with the University Hospital Medical Information Network in Japan, no. 000012970. The study was carried out in an operating theatre of Shinshu University Hospital, Matsumoto, Japan, from February to December 2014. Written informed consent was obtained from each patient with American Society of Anaesthesiologists physical status II or III, who was scheduled for elective surgery under general anaesthesia and required intraoperative monitoring of TOE for open cardiac surgery or aortic surgery, and agreed to be enrolled (Fig. 1).

Use of antiplatelet agents, such as aspirin and clopidogrel, and anticoagulants, such as warfarin, was recorded.

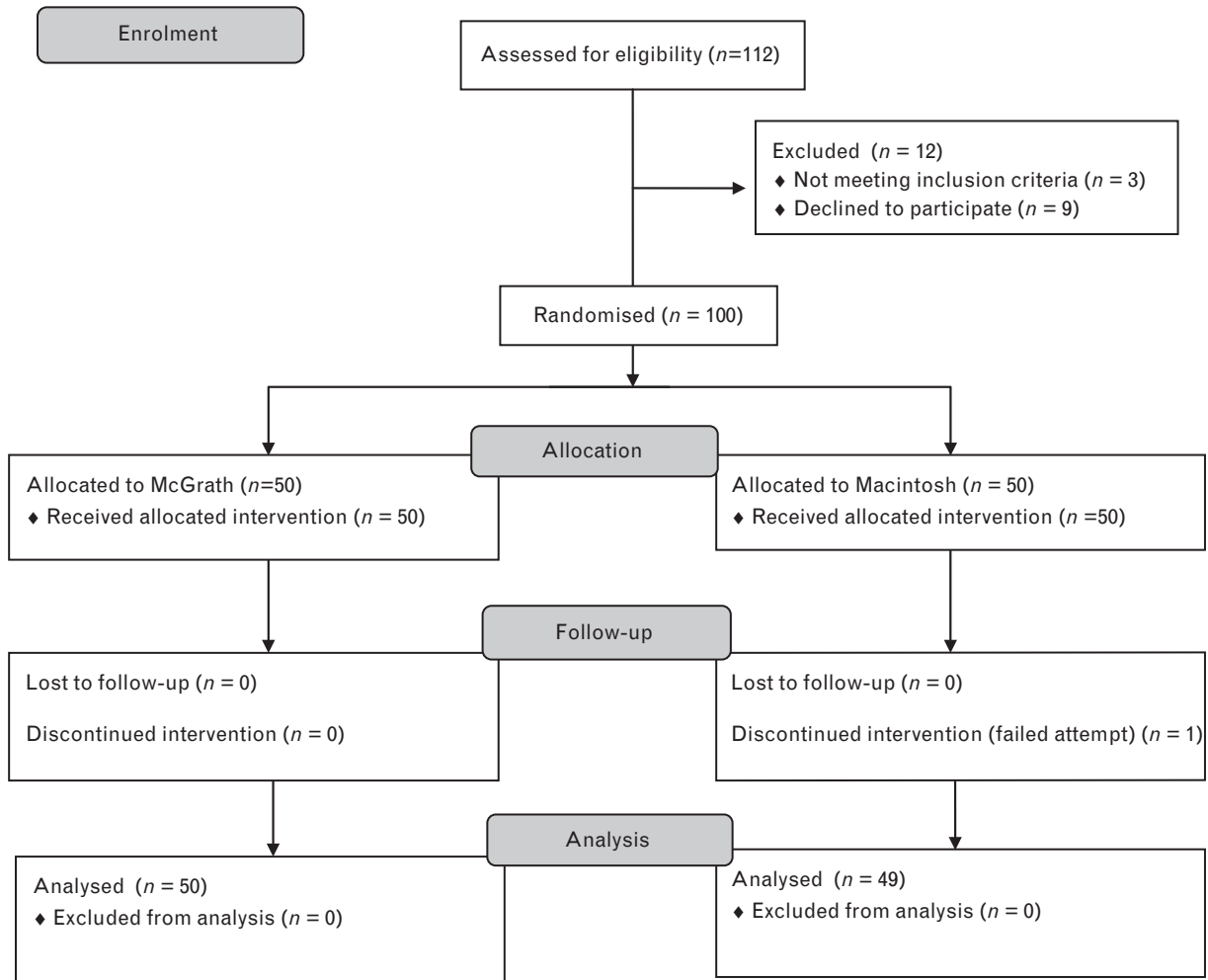
Administration of aspirin, clopidogrel and warfarin was stopped at 7, 14 and 3 days, respectively, before surgery, and warfarin was replaced with intravenous heparin. Patients with sore throat, oropharyngeal infection or neck pain were excluded. Randomisation was by online random number generator software (<https://www.sealedenvelope.com/simple-randomiser/v1/lists>) into either a Macintosh or a McGRATH group using blocks of random sizes of 4. The group allocations were contained in sealed envelopes that were opened in the operating theatre suite after the enrolment procedure had been completed. Three cardiac anaesthesiologists with more than 5 years of experience in intraoperative TOE participated in this study and inserted a TOE probe.

Following a preoperative assessment using the Mallampati classification, anaesthesia was induced in all patients, with fentanyl at 3 to 4  $\mu\text{g kg}^{-1}$  and propofol at 1.5  $\text{mg kg}^{-1}$ . After administration of 0.6  $\text{mg kg}^{-1}$  rocuronium, the trachea was orally intubated using the Macintosh, and at this time, the laryngoscopic view was scored according to the four Cormack and Lehane categories. Endotracheal tubes with inner diameters of 7.0 to 8.5 mm (Mallinckrodt Tapered Seal Guard Tracheal Tube, Covidien, Athlone, Ireland) were used in this study. Anaesthesia was maintained with 1.2 to 1.5% sevoflurane in 40% oxygen and 0.1 to 0.2  $\mu\text{g kg}^{-1} \text{min}^{-1}$  remifentanyl. After tracheal intubation, endotracheal tube cuff pressure was set to and maintained during surgery at 25 to 27  $\text{cmH}_2\text{O}$  using a Hi-Lo Hand Pressure Gauge (Covidien, Athlone, Ireland). The TOE probe (X7-2t; Philips Healthcare, Bothell, Washington, USA) was then covered (CIV-Flex Transducer Cover; CIVCO, Kalona, Iowa, USA) and lubricated with KY Jelly (Johnson and Johnson, Arlington, Texas, USA) before insertion. Patients were positioned in the neutral neck position. The laryngoscope blade was advanced to the epiglottic vallecula and visibility of the oesophageal inlet was evaluated. The Macintosh and the McGRATH were used to visualise the passage of the TOE probe. Repositioning of the blade tip and external laryngeal manipulation was not allowed during the first attempt. Then the TOE probe was inserted using the laryngoscope. If the inlet of the oesophagus was not visible, the probe was introduced into the oesophagus along the posterior pharyngeal wall. When strong resistance was encountered, the TOE probe was withdrawn. In the second and third attempts, repositioning of the blade tip and external laryngeal manipulation was allowed. However, repositioning of the blade tip was restricted to the area of the epiglottic vallecula and repositioning was not allowed in the hypopharynx.

## Outcomes

The outcomes evaluated were visibility of the oesophageal inlet, number of attempts of TOE probe insertion, duration of TOE probe insertion and presence of pharyngeal injury. Visibility was defined as whether the inlet

Fig. 1



Consort flow diagram showing recruitment, allocation, follow-up and analysis. McGRATH, McGRATH MAC; Macintosh, Macintosh laryngoscope.

of the oesophagus was visible or not. The number of attempts for TOE probe insertion was recorded. If the TOE probe could not be placed within three attempts, the case was defined as unsuccessful and the operator was allowed to use the best available technique including use of another laryngoscope to achieve successful insertion. We defined duration of TOE probe insertion as the time in seconds from the time when the mouth was opened until the time when the TOE probe was inserted to a depth of 40 cm. The range of one attempt was defined from inserting the TOE probe into the mouth to pulling the TOE probe out from the mouth or inserting the TOE probe into the oesophagus. When several attempts were needed, the times for TOE probe manipulation were summed, but the times between manipulations were omitted. Once the intraoperative cardiac evaluation was complete, the TOE probe was removed. We evaluated pharyngeal injury as a trauma-related factor. Pharyngeal injury was defined as

observation of laceration and/or haematoma with the McGRATH after the TOE probe had been removed by an anaesthesiologist blind to the group allocation. The same anaesthesiologist recorded the presence or absence of laceration and/or haematoma in the posterior pharyngeal wall, postcricoid area, lateral and medial wall of the piriform sinus and the inlet area to the oesophagus. Injury in other areas such as the oral cavity and upper pharynx was not evaluated.

All patients enrolled in this study were followed up until discharge from hospital. Medical records of those with pharyngeal injury caused by TOE insertion were checked up to 1 month following discharge. We concluded the observation period on 31 December 2014.

### Statistical analysis

In our preliminary study, visibility of the oesophageal inlet in the Macintosh and McGRATH groups was good

**Table 1** Patients' characteristics

	McGRATH group (n = 50)	Macintosh group (n = 50)	P value
Height (cm)	160 ± 11	161 ± 12	0.75
Weight (kg)	60 ± 13	58 ± 12	0.35
Age (years)	69 ± 14	69 ± 13	0.93
Sex (male/female)	32/18	34/16	0.83
BMI	23.0 ± 3.4	22.3 ± 3.3	0.88
ID of ET tube (7/7.5/8/8.5)	12/7/23/8	11/6/25/7	
Antiplatelet and anticoagulants			
Asp alone	7	8	
War alone	7	4	
Clop alone	2	1	
Asp + War	2	1	
Asp + Clop	2	5	
Asp + War + Clop	1	0	
Duration of TOE (min)	363 ± 114	315 ± 126	0.43
Type of operation			
Cardiac surgery	33	31	
Aortic surgery	17	19	

Values are shown as mean ± SD or number. Antiplatelet and anticoagulants, number of patients in whom antiplatelet and anticoagulants were given before surgery; Asp, aspirin; Clop, clopidogrel; Duration of TOE, duration of TOE probe placement during surgery; ET, endotracheal; ID, inner diameter; ID of ET tube, numbers of patients in whom endotracheal tube sizes of 7, 7.5, 8 and 8.5 mm were used; TOE, transoesophageal echocardiography; War, warfarin.

in about 40 and 80%, respectively, indicating that a sample size of 22 patients per group would achieve 80% power. The incidences of pharyngeal mucosal injury in the Macintosh and McGRATH groups were about 20 and 7%, respectively. We estimated that a sample size of 50 per group would achieve 80% power in showing that the McGRATH reduced pharyngeal mucosal injury from 20 to 7%.

The Shapiro–Wilk test was used to assess continuous variables for normality. Normally distributed continuous data were analysed by Student's *t* test. The Mann–Whitney *U* test was used for analysis of the number of TOE insertion attempts. The  $\chi^2$  test was used for analysis of the incidence of pharyngeal mucosal injury and visibility of the oesophageal inlet. All analyses were performed using GraphPad Prism version 6.0 (GraphPad Software, San Diego, California, USA). Data are shown as mean ± SD. A *P* value less than 0.05 was considered statistically significant.

## Results

Fifty patients were recruited to each of the two groups (Fig. 1). Characteristics of patients including BMI and use of antiplatelet agents such as aspirin and clopidogrel and anticoagulants such as warfarin in the two groups were similar (Table 1). The Mallampati classification and Cormack and Lehane grades of the two groups were similar (Table 2). Insertion of the TOE probe was successful in all patients in the McGRATH group but there was one failure in the Macintosh group. In this patient, the data were not analysed further, but the TOE probe was successfully inserted using the McGRATH and intraoperative monitoring was performed uneventfully. As a result, the outcome variables were analysed using data obtained from 50 in the McGRATH and 49 in the Macintosh group.

The percentage of patients in whom the oesophageal inlet was visible was higher in the McGRATH group (88%) than in the Macintosh group (41%) (*P* < 0.01).

**Table 2** Efficacy of McGRATH MAC for transoesophageal echocardiography probe insertion

	McGRATH group (n = 50)	Macintosh group (n = 49)	P value
Mallampati classification (1/2/3)	36/12/2	35/13/1	0.61
Cormack and Lehane grade (I/II/III)	31/18/1	34/16/0	0.53
Visibility of the oesophageal inlet (%)	44 (88)	20 (41)	<0.01
Insertion attempts (1/2/3)	46/4/0	38/9/2	0.039
Duration of TOE probe insertion (s)	21 ± 7	36 ± 13	<0.01
Pharyngeal mucosal injury (%)	2 (4)	8 (16)	0.042
Sites of pharyngeal injury			
Posterior hypopharyngeal wall	2	2	
Piriform sinus	0	3	
Postcricoid area	0	1	
Piriform sinus + hypopharyngeal wall	0	1	
Inlet of oesophagus	0	1	

Values are shown as mean ± SD or number or number (percentages). Insertion attempts, number of TOE probe insertion attempts; Mallampati classification, numbers of patients with Mallampati classifications 1, 2 and 3; Cormack and Lehane grade, numbers of patients with Cormack and Lehane grades I, II and III; Pharyngeal mucosal injury, total numbers of patients with pharyngeal mucosal injury and (percentage); Sites of pharyngeal injury, numbers of patients with mucosal injury of the posterior hypopharyngeal wall, piriform sinus, postcricoid area, piriform sinus and hypopharyngeal wall and inlet of the oesophagus; TOE, transoesophageal echocardiography; Visibility of the oesophageal inlet, number of patients in whom the inlet of the oesophagus was visible and (percentage).

(Table 2). The number of TOE probe insertion attempts was significantly smaller in the McGRATH group than in the Macintosh group ( $P=0.039$ ). The duration of TOE probe insertion was significantly shorter in the McGRATH group than in the Macintosh group ( $P<0.01$ ). The percentage of patients with pharyngeal mucosal injury was significantly smaller in the McGRATH group (4%) than in the Macintosh group (16%,  $P=0.042$ ). Injury of the posterior hypopharyngeal wall was observed in two patients in the McGRATH group, whilst in the Macintosh group, there were injuries to the posterior wall (2), piriform sinus (3), postericoid area (1), piriform sinus and hypopharyngeal wall (1) and inlet of oesophagus (1) (Table 2).

We re-analysed the data for all patients in both the groups according to whether the oesophageal inlet was visible or not. The oesophageal inlet was visible in 64 and not visible in 35 patients in the two groups. The number of patients with pharyngeal mucosal injury was significantly smaller in patients whose oesophageal inlet was visible (3/64, 5%) than in patients whose oesophageal inlet was not visible (7/35, 20%,  $P=0.018$ ).

All patients including those with pharyngeal injury were discharged from the hospital without further complications. Other complications such as injury in the oral cavity and mouth because of TOE insertion were not observed. Medical record review demonstrated no serious injuries such as oesophageal rupture or gastric bleeding in either group.

## Discussion

Patients under general anaesthesia are unable to swallow to facilitate insertion of a TOE probe and cannot respond to possibly injurious probe manipulation. In addition, insertion of a TOE probe in anaesthetised patients is sometimes difficult because of the loss of upper airway muscle tone and the presence of an endotracheal tube.<sup>10</sup> As a result, severe and life-threatening complications associated with TOE such as orogastric tract perforation, gastrointestinal bleeding<sup>5</sup> and endotracheal tube malposition have all been reported in anaesthetised patients,<sup>1,13</sup> making safe insertion during surgery a clinical goal.<sup>9</sup>

Na *et al.*<sup>10</sup> have shown that the use of the Macintosh reduces pharyngeal injury associated with TOE probe insertion in anaesthetised patients. They suggest that the key to reducing the incidence of a TOE-related oropharyngeal injury is visualisation of its passage. To prevent unintended TOE probe contact with the piriform sinus and glottis, the oesophageal inlet must be seen to confirm the direction of the TOE probe. To achieve visualisation of the oesophageal inlet, obtaining at least a view of the posterior portion of the glottis is necessary. With the Macintosh, to obtain a view of the glottis, the oral, pharyngeal and laryngeal axes must be aligned. In

anaesthetised patients, an endotracheal tube obstructs the view of the glottis and makes it difficult to visualise the oesophageal inlet. Also, the use of adhesive tape to secure a tracheal tube reduces mouth opening.

The use of a video laryngoscope for TOE probe insertion has not been studied before, but previous studies have shown that several video laryngoscopes such as the McGRATH, the Glidescope (Saturn Biomedical Systems, British Columbia, Canada) and the Airtraq (Prodol Meditec S.A., Vzcaya, Spain) all improve the view of the glottis compared with the Macintosh.<sup>14–17</sup> With the McGRATH, alignment of the axes is unnecessary, and it enables easy visualisation of the larynx and oesophageal inlet beyond obstacles and is less affected by the presence of an endotracheal tube. The oesophageal inlet was visible in a significantly larger percentage of patients in the McGRATH group than in the Macintosh group. The number of TOE probe insertion attempts and duration of insertion were significantly less in the McGRATH group than in the Macintosh group. Although we could not see the oesophageal inlet and failed to insert the TOE probe in one patient in the Macintosh group, we could easily see the oesophageal inlet in that patient by using the McGRATH. In summary, the McGRATH was superior to the Macintosh in enabling the visualisation of the TOE probe passing through the oesophageal inlet, particularly when placement was difficult.

There are several case reports describing the efficacy of the Glidescope and the Airtraq video laryngoscopes for TOE probe insertion when the Macintosh was unsuccessful.<sup>18,19</sup> Thus, in addition to McGRATH, other types of video laryngoscopes may aid insertion of a TOE probe in anaesthetised patients. However, the thickness of the blades of the McGRATH, GlideScope and Airtraq varies, at 12, 14 and 18 mm, respectively. The slim blade of McGRATH may be more beneficial for visualisation of the glottis and manipulation of the TOE probe in the oropharynx occupied by an endotracheal tube.

It is likely that visualisation of TOE probe passage and confirmation of its direction avoids traumatic manipulation in the pharynx and reduces the incidence of injury related to insertion. The incidence of injury was significantly lower in patients in whom the oesophageal inlet was visible than in those whose inlet was not visible, though it is uncertain whether visualisation of TOE probe passage is responsible for a reduction in the incidence of perforation of the hypopharynx and upper oesophagus. As mucosal injury and orogastric tract perforation are likely to be caused by excessive pressure generated through the tip of the TOE probe, visualising its passage should reduce the incidence of these complications. An additional advantage of visualisation is that education is greatly facilitated if both teachers and students can see exactly where they are manipulating the probe in the pharynx. Thus, visualisation of TOE

manipulation has a potential benefit for improving patient safety.

In this study, the incidence of pharyngeal mucosal injury was much higher than that reported by Na *et al.*<sup>10</sup> There may be two explanations for this. First, the patients enrolled in our study were scheduled to undergo cardiovascular surgery and were given heparin during surgery. The patients in the study by Na *et al.* were scheduled for noncardiac surgery. Second, as we used TOE as intraoperative monitoring during cardiovascular surgery, the mean duration of TOE examination (5 to 6 h) in this study was longer than that in the study by Na *et al.* (20 min).

Our study has limitations. First, the sample size might be too small to identify rare but serious complications of TOE probe insertion. Second, we simplified the grade of visibility of the oesophageal inlet and did not allow repositioning of the blade tip to reduce observation bias. Bias arising from inability to blind the investigators to the group allocation remains difficult to eliminate. Third, we did not assess the occurrence of odynophagia and/or dysphagia after surgery. Owing to the fact that most of the patients underwent cardiovascular surgery and because the trachea was intubated for a relatively long time, TOE insertion was not the only source of odynophagia and dysphagia. Fourth, as the TOE probe is manipulated blindly after insertion into the oesophageal inlet, visualisation does not prevent injury and possible perforation in the middle to lower oesophagus and stomach.<sup>6</sup>

In conclusion, the McGRATH provides a better view of the oesophageal inlet and is a useful aid in TOE probe placement, possibly reducing the incidence of pharyngeal injury related to insertion in anaesthetised patients.

### Acknowledgements related to this article

Assistance with the study: none.

Financial support and sponsorship: this work was supported by grants to TI (grant No. 24791587) and MK (grant No. 21390432) from the Japan Society for the Promotion of Science, Tokyo, Japan.

Conflict of interest: none.

Presentation: none.

### References

- 1 Kallmeyer IJ, Collard CD, Fox JA, *et al.* The safety of intraoperative transesophageal echocardiography: a case series of 7200 cardiac surgical patients. *Anesth Analg* 2001; **92**:1126–1130.
- 2 Min JK, Spencer KT, Furlong KT, *et al.* Clinical features of complications from transesophageal echocardiography: a single-center case series of 10,000 consecutive examinations. *J Am Soc Echocardiogr* 2005; **18**:925–929.
- 3 Lenon MJ, Gibbs NM, Weightman WM, *et al.* Transesophageal echocardiography-related gastrointestinal complications in cardiac surgical patients. *J Cardiothorac Vasc Anesth* 2005; **19**:141–145.
- 4 Bavalia N1, Anis A, Benz M, *et al.* Esophageal perforation, the most feared complication of TEE: early recognition by multimodality imaging. *Echocardiography* 2011; **28**:E56–E59.
- 5 Piercy M, McNicol L, Dinh DT, *et al.* Major complications related to the use of transesophageal echocardiography in cardiac surgery. *J Cardiothorac Vasc Anesth* 2009; **23**:62–65.
- 6 Kharasch E, Sivarajan M. Gastroesophageal perforation after intraoperative transesophageal echocardiography. *Anesthesiology* 1996; **85**:426–428.
- 7 Spahn DR, Schmid S, Carrel T, *et al.* Hypopharynx perforation by a transesophageal echocardiography probe. *Anesthesiology* 1995; **82**:581–583.
- 8 Bakhos D, Cottier JP, Beutter P, Morinière S. Hypopharyngeal perforation: an unusual complication of transesophageal echocardiography. *Ear Nose Throat J* 2011; **90**:E1–E2.
- 9 Aviv JE, Di Tullio MR, Homma S, *et al.* Hypopharyngeal perforation near-miss during transesophageal echocardiography. *Laryngoscope* 2004; **114**:821–826.
- 10 Na S, Kim CS, Kim JY, *et al.* Rigid laryngoscope-assisted insertion of transesophageal echocardiography probe reduces oropharyngeal mucosal injury in anesthetized patients. *Anesthesiology* 2009; **110**:38–40.
- 11 Noppens RR, Mobus S, Heid F, *et al.* Evaluation of the McGrath Series 5 videolaryngoscope after failed direct laryngoscopy. *Anaesthesia* 2010; **65**:716–720.
- 12 Shippey B, Ray D, McKeown D. Use of the McGrath<sup>®</sup> videolaryngoscope in the management of difficult and failed tracheal intubation. *Br J Anaesth* 2008; **100**:116–119.
- 13 Hilberath JN, Oakes DA, Sherman SK, *et al.* Safety of transesophageal echocardiography. *J Am Soc Echocardiogr* 2010; **23**:1115–1127.
- 14 Savoldelli GL, Schiffer E, Abegg C, *et al.* Comparison of the Glidescope<sup>®</sup>, the McGrath<sup>®</sup>, the Airtraq<sup>®</sup> and the Macintosh laryngoscopes in simulated difficult airways. *Anaesthesia* 2008; **63**:1358–1364.
- 15 Maharaj CH, O'Croinin D, Curley G, *et al.* A comparison of tracheal intubation using the Airtraq<sup>®</sup> or the Macintosh laryngoscope in routine airway management: a randomised, controlled clinical trial. *Anaesthesia* 2006; **61**:1093–1099.
- 16 Jungbauer A, Schumann M, Brunkhorst V, *et al.* Expected difficult tracheal intubation: a prospective comparison of direct laryngoscopy and video laryngoscopy in 200 patients. *Br J Anaesth* 2009; **102**:546–550.
- 17 Hyuga S, Sekiguchi T, Ishida T, *et al.* Successful tracheal intubation with McGrath<sup>®</sup> MAC video laryngoscope after failure with the Pentax-AWS<sup>®</sup> with cervical spine immobilization. *Can J Anesth* 2012; **59**:1154–1155.
- 18 Hirabayashi Y. GlideScope-assisted insertion of a transesophageal echocardiography probe. *J Cardiothorac Vasc Anesth* 2007; **21**:628.
- 19 Hirabayashi Y, Okada O, Seo N. Airtraq laryngoscope for the insertion of a transesophageal echocardiography probe. *J Cardiothorac Vasc Anesth* 2008; **22**:33.