

## Rapid Progression of Hidradenitis Suppurativa in the Lower Leg of a Patient with Psoriasis Vulgaris

Asuka Tanaka, Yasufumi Goto, Maiko Iwade, Hisashi Uhara and Ryuhei Okuyama\*

Department of Dermatology, Shinshu University School of Medicine, Asahi 3-1-1, Matsumoto, 390-8621 Japan. \*E-mail: rokuyama@shinshu-u.ac.jp

Accepted May 4, 2011.

Hidradenitis suppurativa (HS) occurs chiefly in areas rich in apocrine glands, such as the axillae and the genitocrural region, and was previously thought to originate from apocrine portal closure with subsequent bacterial infection of the apocrine sweat glands. However, it is now suggested that HS is an inflammatory disease originating from follicular occlusion rather than apocrine portal closure (1–3). Here, we report a case of HS, which developed rapidly on the leg, and may have been related to psoriasis vulgaris.

### CASE REPORT

A 44-year-old man was referred to our hospital due to a reddish eruption with discharge on the right lower leg. The patient had a 17-year history of psoriasis vulgaris, which had been treated with topical glucocorticoids and activated vitamin D<sub>3</sub>. He was obese (body mass index: 40.1). Three months prior to presentation, he noted a coin-sized reddish eruption with pain on the right lower leg. Previously, psoriatic erythema and plaque had occurred at the same site. He stopped using glucocorticoid and vitamin D<sub>3</sub> ointment, and the eruption enlarged rapidly in size together with discharge. He had not suffered from acne conglobata, dissecting cellulitis of the scalp, or Crohn's disease. In addition, there was no family history of HS. Physical examination revealed the presence of a raised reddish plaque with papillomatous surface measuring 8 × 5 cm on the lateral side of the right lower leg (Fig. 1a). The central part of the plaque had purulent draining sinuses with deep-seated nodule, and the peripheral part had mild scar formation. *Escherichia coli* was confirmed on culture of the discharge, whereas neither mycobacteria nor fungi were detected. Laboratory examination was within the normal range. Skin biopsy of the lesion showed epithelial hyperplasia with chronic inflammatory cell infiltrate involving neutrophils and histiocytes. The lesion did not respond to skin disinfection with chlorhexidine gluconate or oral cefotiam hexetil. However, bacterial cultures from the discharge isolated only a small number of colonies of *Staphylococcus epidermidis* on several occasions, indicating a secondary colonization. Based on clinical and histopathological features, a diagnosis of HS was made. The lesion was resected under local anesthesia. Histopathologically, it revealed dilated infun-

dibula containing keratinous material, acanthotic hyperplasia with reticular elongation, formation of sinus tracts lined by keratinocytes, and underlying fibrosis with mixed suppurative and granulomatous inflammatory infiltrates (Fig. 1b). Different from psoriasis, parakeratosis was absent and the stratum granulosum was intact. No recurrence of the purulent lesion occurred over the follow-up period of 8 months.

### DISCUSSION

HS usually occurs in intertriginous areas (1–3), atypical locations are not uncommon (4). However, the occurrence in the lower legs a site devoid of apocrine glands is unusual, and we have found only one previous report of such a case (5). Our case showed clinically tender plaque with purulent discharge, which did not respond to antibiotics. Histopathologically, there was follicular hyperkeratosis with plugging and inflammation as well as sinus formation with fibrosis. Orthokeratosis in this case did not coincide with histopathological feature in psoriasis, which led to a diagnosis of HS, not psoriasis vulgaris associated with secondary infection. The primary mechanism of the disease is hyperkeratinization of the follicular infundibulum resulting in occlusion of the follicle followed by its rupture with subsequent inflammation (1–3). Apocrine glands become secondarily affected. Intriguingly, inflammation occurs not only in the follicle but also in interfollicular epidermis (1, 2), where orthokeratotic epidermal hyperplasia is found together with subepidermal interfollicular inflammatory infiltration.

The prevalence of psoriasis vulgaris in patients with HS was reported to be 3.9% (2), i.e. only slightly higher than in the general population. This suggests that psoriasis does not directly promote the occurrence of HS. Rather, obesity seems likely to be associated with the occurrence of HS (6). The patient's obesity may have resulted in follicular blockage due to mechanical stress

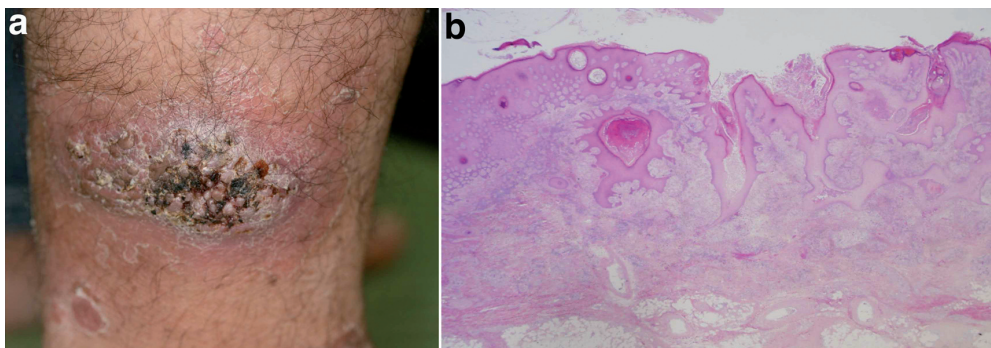


Fig. 1. Clinical and histopathological views. (a) Raised reddish plaque with purulent draining sinuses on the lateral side of the right lower leg. (b) Acanthotic hyperplasia with follicular plugging and sinus formation, and underlying fibrosis with mixed suppurative and granulomatous inflammatory infiltrates (Hematoxylin–eosin staining, original magnification: ×10).

and provided a basis for the occurrence, because the skin had been rubbed by tight cloth. Further, mechanical stress seems to develop the occurrence on the lower leg due to tight socks.

A tender plaque with discharge developed rapidly in our patient. HS is usually insidious, but it took only 3 months to form the lesion. Recently, tumor necrosis factor- $\alpha$  inhibitors have demonstrated efficacy in HS (3, 7), suggesting that the inflammation cascade is associated with the pathogenesis of this condition, similar to psoriasis vulgaris (8). In this case, inflammatory aberration in psoriatic skin may accelerate inflammation around hair follicles and follicular occlusions, leading to rapid formation of HS.

## REFERENCES

1. von Laffert M, Helmbold P, Wohlrab J, Fiedler E, Stadie V, Marsch WC. Hidradenitis suppurativa (acne inversa): early inflammatory events at terminal follicles and at interfollicular epidermis. *Exp Dermatol* 2009; 19: 533–537.
2. Von Laffert M, Stadie V, Wohlrab J, Marsch WC. Hidradenitis suppurativa/acne inversa: bilocated epithelial hyperplasia with very different sequelae. *Br J Dermatol* 2011; 164: 367–371.
3. Alikhan A, Lynch PJ, Eisen DB. Hidradenitis suppurativa: a comprehensive review. *J Am Acad Dermatol* 2009; 60: 539–561; quiz 62–63.
4. Canoui-Poitrine F, Revuz JE, Wolkenstein P, Viallette C, Gabison G, Pouget F, et al. Clinical characteristics of a series of 302 French patients with hidradenitis suppurativa, with an analysis of factors associated with disease severity. *J Am Acad Dermatol* 2009; 61: 51–57.
5. Weiner J, Lewis JE, Samitz MH. Hidradenitis suppurativa occurring on the leg. *Cutis* 1976; 17: 888–891.
6. Revuz J. Hidradenitis suppurativa. *J Eur Acad Dermatol Venereol* 2009; 23: 985–998.
7. Haslund P, Lee RA, Jemec GB. Treatment of hidradenitis suppurativa with tumour necrosis factor-alpha inhibitors. *Acta Derm Venereol* 2009; 89: 595–600.
8. Etehad P, Greaves MW, Wallach D, Aderka D, Camp RD. Elevated tumour necrosis factor-alpha (TNF-alpha) biological activity in psoriatic skin lesions. *Clin Exp Immunol* 1994; 96: 146–151.