Usefulness of gastroduodenal biopsy in the differential diagnosis of systemic AH amyloidosis from systemic AL amyloidosis

Short title: Gastroduodenal biopsy of AH amyloidosis

Shojiro Ichimata,[1] Mikiko Kobayashi,[1] Hisashi Shimojo,[1] Nagaaki Katoh,[2] Masahide Yazaki[3, 4] and Hiroyuki Kanno[1]

[1]Department of Pathology, Shinshu University School of Medicine, Matsumoto, Japan

[2]Department of Neurology and Rheumatology, Shinshu University School of Medicine, Matsumoto, Japan

[3]Department of Clinical Laboratory Sciences, Shinshu University School of Health Sciences, Matsumoto, Japan

[4]Institute for Biomedical Sciences, Shinshu University, Matsumoto, Japan

Author contributions: M. Kobayashi and H. Kanno designed the research study. S. Ichimata performed the research. S. Ichimata and M. Kobayashi analysed the data. H. Shimojo and H. Kanno assisted with data analysis and interpretation. N. Katoh and M.

Yazaki assisted with patient selection. S. Ichimata wrote the paper. S. Ichimata, M. Kobayashi, H. Shimojo, N. Katoh, M. Yazaki and H. Kanno read and revised the paper, and agreed with the paper.

Correspondence: Mikiko Kobayashi, Department of Pathology, Shinshu University School of Medicine, 3-1-1 Asahi, Matsumoto, 390-8621, Japan

Tel: +81-263-37-2607; Fax: +81-263-37-2609; E-mail: mikko@shinshu-u.ac.jp

Conflicts of interest: The authors declare no conflicts of interest.

Abstract

Aims: Immunoglobulin (Ig) heavy chain amyloidosis (AH amyloidosis) is Ig-related amyloidosis classified together with Ig light chain amyloidosis (AL amyloidosis). Compared with AL amyloidosis, patients with AH amyloidosis exhibit a better prognosis and they may not need an aggressive treatment. Thus, the accurate diagnosis is essential for management of Ig-related amyloidosis patients. For definite diagnosis of AH amyloidosis, biochemical analyses are usually needed. However, these analyses can be performed in limited facilities. Therefore, the characteristic deposition pattern of AH amyloidosis in routine histopathological examination of biopsy specimens, such as gastrointestinal biopsy, if present, may help in the selection of cases for further biochemical analyses.

Methods and results: Gastroduodenal biopsy specimens obtained from 3 cases of biochemically-confirmed AH amyloidosis and 21 cases of immunohistochemically-confirmed AL amyloidosis were examined, and the following distinctive histopathological features of AH amyloidosis were pointed out: 1) AH amyloid deposition was detectable with Congo red staining in the gastroduodenal biopsy specimens; 2) AH amyloid deposition was characteristically observed on the capillary wall of duodenal villi (*dotted line-like deposition in the villi*), and this pattern

was not observed in AL amyloidosis.

Conclusion: These findings help to select cases for biochemical analyses for definite diagnosis of AH amyloidosis, and may lead to the accumulation of cases and improve our understanding of systemic AH amyloidosis.

Key words: Amyloidosis, Gastroduodenal biopsy, Immunoglobulin heavy chain amyloidosis, Immunoglobulin light chain amyloidosis, Systemic amyloidosis

Introduction

Immunoglobulin (Ig) light chain amyloidosis (AL amyloidosis) and Ig heavy chain amyloidosis (AH amyloidosis) are both Ig-related amyloidosis mainly caused by plasma cell neoplasms. Clonal plasma cells secrete monoclonal Ig, free light chain, and truncated heavy chain, with or without structural abnormalities.[1,2] Among these, AL amyloidosis is caused by the deposition of light chain fragment-derived amyloid fibrils, and AH amyloidosis is caused by the deposition of heavy chain fragment-derived amyloid. Systemic AL amyloidosis is the most common type of systemic amyloidosis and it accounts for approximately two-thirds of all systemic amyloidosis cases,[3] whereas systemic AH amyloidosis is a rare disease and only 17 cases have been reported.[1,4-15] Both types of Ig-related amyloidosis frequently affect the kidney. However, compared with patients with AL amyloidosis, those with AH amyloidosis have a favorable prognosis because of the less frequent cardiac involvement,[14] which is the leading cause of death in AL amyloidosis. Thus, the differential diagnosis between AH and AL amyloidosis is important for clinical management and therapeutic strategies.

The diagnosis of amyloidosis is based on histopathological findings. After the histopathological confirmation of amyloid deposition, the typing of the amyloid protein is essential for management of the patients. Amyloid A (AA)-, transthyretin- and

beta2-microglobulin-derived amyloid can be readily detected with immunohistochemistry. However, immunohistochemical detection of AL amyloid deposition is difficult because the Ig light chain variable region has extreme diversity and the length of the constant region included in AL amyloid deposition varies.[16,17] Some useful antibodies have been reported, but reliable and commercially available antibodies are still limited.[18] Moreover, immunohistochemical detection of AH amyloid deposition is also difficult because AH amyloid protein often lacks the Fc portion, which is recognized by most antibodies reacting with Ig heavy chains.[1] Therefore, biochemical analyses, such as amino acid sequence analysis of extracted amyloid proteins, laser micro-dissection and mass spectrometry (LMD/MS), and liquid chromatography-tandem mass spectrometry (LC-MS/MS), are frequently required for definite diagnosis of AH amyloidosis.[1,5,5,9-15] However, these analyses can be performed in limited facilities.

To detect amyloid deposition in patients with systemic amyloidosis, biopsies of abdominal adipose tissue, bone marrow and gastrointestinal (GI) tract are frequently performed due to their safety and high detection rate. The detection sensitivity of AL amyloid deposition in abdominal adipose tissue, bone marrow and GI tract are reported as approximately 90%,[19] 60%,[20] and 50-100%,[19, 21-25] respectively. However, the

detection sensitivity of AH amyloid deposition with abdominal adipose tissue and bone marrow is low, reported as 15% and 40%, respectively.[14] Moreover, there is no report evaluating AH amyloid deposition in the GI tract. We previously reported the detailed histopathological findings from a systemic AH amyloidosis patient.[26] In this patient, amyloid deposition was found in the glomeruli of kidneys, mucosa of the GI tract, endocrine organs and choroid plexus, with a characteristic deposition pattern of capillary wall predominance. This capillary-predominant deposition pattern in the GI tract is not common in AL amyloidosis. Therefore, we assumed that gastroduodenal biopsy may be useful to detect AH amyloid deposition.

In this study, we examined the usefulness of gastroduodenal biopsy for the detection of AH amyloid deposition using three cases of biochemically-confirmed AH amyloidosis.[9-11] In addition, we assessed whether gastroduodenal biopsy specimens are useful for the differential diagnosis between AH and AL amyloidosis using gastroduodenal biopsy specimens of 21 cases of immunohistochemically-confirmed AL amyloidosis.

Materials and Methods

Patients

AH amyloidosis patients

Three patients with AH amyloidosis (AH 1-3) who underwent gastroduodenal biopsy in Shinshu University Hospital from 2002 to 2015 were identified. All patients were confirmed to exhibit monoclonal immunoglobulin components by serum and/or urine immunofixation electrophoresis. Amyloid deposition was confirmed by Congo red staining. All of these specimens were immunohistochemically evaluated with commercially available antibodies (anti-AA, anti-fibrinogen, anti-beta2-microglobulin and anti-transthyretin antibodies) and polyclonal antibodies against Igκ [rabbit sera immunized with short peptide of the constant-region, amino acids 116-133; anti-κ (116-133)] and Igλ [rabbit sera immunized with short peptide of the constant-region, amino acids 118-134; anti-λ (118-134)] light chain (kindly provided from Dr. Yoshinobu Hoshii, Yamaguchi University, Ube, Japan),[16] and all yielded negative results. The definite diagnosis of AH amyloidosis was confirmed by amino acid sequence analysis of extracted amyloid proteins (2 cases; AH 1 and 2) or by LC-MS/MS (1 case; AH 3).[9-11] There was no evidence of immunoglobulin light chain in the amino acid sequence analysis or in the LC-MS/MS analysis in all three patients.

AL amyloidosis patients

Eight consecutive patients with ALκ amyloidosis (ALκ 1-8) and thirteen consecutive patients with ALλ amyloidosis (ALλ 1-13) who underwent gastroduodenal biopsy at Shinshu University Hospital from 2012 to 2015 and 2014 to 2015, respectively, were identified. All patients were confirmed to exhibit monoclonal immunoglobulin components by serum and/or urine immunofixation electrophoresis. Amyloid deposition was confirmed by Congo red staining. All of these specimens were immunohistochemically evaluated with commercially available antibodies (anti-AA, anti-fibrinogen, anti-beta2-microglobulin and anti-transthyretin antibodies) and all yielded negative results. ALκ amyloidosis was confirmed by immunohistochemistry with anti-κ (116–133) antibodies[16] and anti-human kappa light chain antibodies (clone H16-E, ready to use; DB BIOTECH, Kosice, Slovak Republic)[18], and ALλ amyloidosis was confirmed by immunohistochemistry with anti-λ (118–134) antibodies.[16] These antibodies against AL amyloid fibrils have been reported to exhibit high specificity and reactivity,[16,18] and the utility has established.[27]

Tissue samples

Most of the patients described above underwent gastroduodenal biopsy several times before and after treatment. Then, the specimens before treatment for each patient were

selected for further analyses. All materials were fixed in 10% neutral-buffered formalin and embedded in paraffin. Serial tissue sections (3-μm-thickness for HE-staining and immunostaining and 6-μm-thickness for Congo red-staining) were prepared from paraffin blocks and stained. This study was approved by the ethics committee of Shinshu University School of Medicine, Matsumoto, Japan in March 22, 2016 (No. 3380).

Histopathological evaluation

Amyloid deposition was evaluated in each layer of the gastroduodenal wall; lamina propria mucosa, muscularis mucosa and submucosa. Furthermore, duodenal lamina propria mucosa was divided into two areas, the villus area and the non-villus area. Amyloid deposition was confirmed by Congo red-staining in bright field and under polarized light, and estimated semi-quantitatively according to the following criteria; 4+ (amyloid deposition was identifiable by using 4x objective and 10x ocular lenses), 3+ (10x objective and 10x ocular lenses), 2+ (20x objective and 10x ocular lenses), + (40x objective and 10x ocular lenses), and - (none). All specimens were evaluated independently by two experienced pathologists (SI and MK).

Immunohistochemistry

To evaluate the histological localization of amyloid deposition, we performed immunostaining using monoclonal antibodies for CD34 (clone QBEnd10, dilution 1:800; Beckman Coulter, Brea, USA) and CD31 (clone JC/70A, dilution 1:40; DAKO, Hamburg, Germany) as endothelial markers, and for type IV collagen (clone CIV 22, dilution 1:50; DAKO) as a basement membrane marker. After endogenous peroxidase inhibition with 0.3% H_2O_2 for 30 min, antigen retrieval was performed by heating sections in 0.01M EDTA buffer (pH 8.0) in a microwave oven at 600W for 30 min (CD31 and CD34) or in 0.05% trypsin solution in a 37 ºC water bath for 60 min (type IV collagen). Incubation with primary antibodies was performed for 90 min at room temperature (CD34) or overnight at 4ºC (CD31 and type IV collagen), and subsequent signal development was performed using the immunoenzyme polymer method (Histofine Simple Stain MAX PO Multi; Nichirei Biosciences, Tokyo, Japan) with 3,3'-diaminobenzidine as the chromogen. The sections were counterstained with hematoxylin. Surgically resected gastric mucosa and duodenal mucosa specimens obtained from a non-amyloidosis patient were used as a control of normal structures.

Double staining with immunostaining and Congo red staining

For the detailed observation of histopathological localization of amyloid deposition in the gastroduodenal biopsy specimens of AH amyloidosis, we performed double immunostaining and Congo red staining. After immunostaining for endothelial markers (CD31 or CD34) and a basement membrane marker (type IV collagen), Congo red staining was performed.

Results

Duodenal biopsy specimens

The representative histopathological findings are shown in Figure 1. In AH amyloidosis, no massive or diffuse amyloid deposition was observed (Figure 1A and 1B). Only a small amount of amyloid deposition was recognizable on the wall of small vessels, mainly in the submucosa in bright field observation (Figure 1A). In addition, we clearly observed amyloid deposition in the villi and submucosa under polarized light (Figure 1B, C). Especially in the villi, dotted line-like fine amyloid deposition was seen just beneath the epithelial basement membrane (*dotted line-like deposition in the villi*) (Figure 1C). In contrast, in both ALκ and ALλ amyloidosis, massive and diffuse amyloid deposition, mainly located in the stroma and the small vessels of the muscuralis mucosae and submucosa, was observed (Figure 1D, E, G, H). However, *dotted line-like*

deposition in the villi was not identified (Figure 1F, I).

Then, we evaluated the amyloid deposition according to the scoring system described in Materials and Methods. The results are summarized in Table 1. Both AH and AL amyloid deposition were detectable in duodenal biopsy specimens. The differences in histopathological characteristics of amyloid deposition between AH and AL amyloidosis were size, pattern, and sites. First, the size and pattern of AH amyloid deposition were fine and focal (undetectable with 4x objective lens), whereas those of AL amyloid deposition were massive and sometimes diffuse (detectable with 4x objective lens in most AL amyloidosis cases). Second, amyloid deposition in the villi was detectable in all three AH amyloidosis cases. In contrast, AL amyloid was mainly deposited in the muscuralis mucosa and submucosa, and amyloid deposition was undetectable in the villi in most cases of AL amyloidosis even using the 40x objective lens and polarized light. Only one case of ALκ amyloidosis (ALκ 4) demonstrated amyloid deposition in the villi; however, its deposition pattern was massive and diffuse (detectable with 4x objective lens), distinct from that of AH amyloidosis.

As for the deposition of AH amyloid, we assumed that the histological localization of the *dotted line-like deposition in the villi* was corresponding with the capillaries of the villi. Thus, we examined the histological localization of AH amyloid deposition using

serial slides with Congo red staining and immunostaining for endothelial markers. The localization of AH amyloid deposition seemed to correspond with the wall of the capillaries in the villi (Figure 2). Therefore, to demonstrate more exactly the association between AH amyloid deposition and the capillary structure, we performed double immunostaining and Congo red staining. With regard to the identification of capillary structure, immunohistochemistry for a basement membrane marker, type IV collagen, was also used in addition to that for endothelial markers. Representative histopathological findings are shown in Figure 3. In double-stained specimens, amyloid deposition was identified on the wall of capillaries, which were positive for CD31 and type IV collagen (Figure 3C, F). From these findings, we concluded that characteristic deposition of AH amyloid in the duodenum (*dotted line-like deposition in the villi*) was the deposition on the wall of capillaries in the villi.

Gastric biopsy specimens

Submucosal tissue was not included in many gastric biopsy specimens; therefore, we cannot evaluate amyloid deposition in submucosa in the gastric biopsy specimens. The representative histopathological findings are shown in Figure 4 and results of amyloid deposition score are summarized in Table 2. In both AH and AL amyloidosis, the size

and pattern of amyloid deposition in gastric biopsy specimens were almost similar to those in duodenal biopsy specimens. The differences in site-specific amyloid deposition, such as *dotted line-like deposition in the villi* of duodenal biopsy, were not identified between AH and AL amyloidosis.

Discussion

Since Eulitz et al. described the first case of AH amyloidosis in 1990,[2] there have been only 17 reported cases of systemic AH amyloidosis.[1,4-15] AH amyloidosis is regarded as a rare disease. However, Nasr et al. performed amyloid typing of renal Ig-related amyloidosis by immunofluorescence and/or LMD/MS, and reported that renal AH amyloidosis comprised 2.3% (5/218 patients).[14] Thus, there may be many more cases of AH amyloidosis. Most patients with AH amyloidosis have not been recognized, and have likely been diagnosed with AL amyloidosis because both AH and AL amyloidosis are usually accompanied by plasma cell neoplasms, and immunohistochemical discrimination is difficult.[16] In this study from Nasr, heavy and light chain amyloidosis (AHL amyloidosis) also comprised 5.0% (11/218 patients). As our study did not evaluate AHL amyloidosis, further investigation is needed regarding AHL amyloid deposition in gastroduodenal biopsy specimens.

Our study demonstrated the following novel histopathological findings for AH amyloidosis: 1) AH amyloid deposition was detectable in the gastroduodenal biopsy specimens; 2) AH amyloid deposition in the duodenum exhibited the characteristic deposition pattern, *dotted line-like deposition in the villi*, and this feature was not observed in AL amyloidosis. In the current study, AL amyloidosis cases are thought to be more advanced than AH amyloidosis cases, comparing both amyloidosis in the size and pattern of deposition. Therefore, we thought that *dotted line-like deposition in the villi* was the characteristic feature of AH amyloidosis because this feature was not found in AL amyloidosis cases which thought to be more advanced. It is important for the detection of this characteristic AH amyloid deposition to use a high-magnification objective lens under polarized light because in Congo red-stained specimens, small amyloid deposition is sometimes undetectable under the bright field observation and that can be identified using polarized light.[28] From the deposition pattern alone, AA amyloidosis may also be considered. AA amyloidosis also exhibits amyloid deposition in the duodenal villi.[29] However, AA amyloidosis can be distinguished from AH amyloidosis by clinically and immunohistochemically. Clinically, AA amyloidosis is a secondary amyloidosis caused by chronic inflammatory disease such as rheumatoid arthritis, whereas Ig-related amyloidosis including AH amyloidosis is mainly caused by

plasma cell neoplasms. Immunohistochemically, AA amyloid deposition can be readily detected.

The distribution of the characteristic dotted line-like deposition of AH amyloidosis in the duodenal villi corresponds with fenestrated capillaries, which are mainly located just beneath the absorptive epithelial cells and form a unique capillary network. These fenestrated capillary networks distribute to specific tissues such as glomeruli of the kidney, choroid plexus, endocrine organs and villi of the small intestine. The distribution of fenestrated capillaries corresponds with AH amyloid deposition in our previous autopsy case.[26] In addition, the following characteristic features of AH amyloidosis can be clearly explained by the presence or absence of fenestrated capillaries: 1) predominant involvement of the kidney; 2) improved patient prognosis due to less frequent involvement of the heart, and 3) the lower detection sensitivity of amyloid deposition in the subcutaneous adipose tissue and bone marrow.

In the current study, we revealed that gastroduodenal biopsy can detect AH amyloid deposition and duodenal biopsy is useful for the differential diagnosis of AH amyloidosis from AL amyloidosis. When a patient is suspected of Ig-related amyloidosis clinically, we recommend duodenal biopsy as initial examination. When *dotted line-like deposition in the villi* is found in duodenal biopsy specimens, further

biochemical analyses are recommended for definitive diagnosis of AH amyloidosis. When the amount of the deposition is too little to perform biochemical analyses, additional biopsy from the affected site (e.g. kidney) is recommended. We can select cases that need additional invasive biopsy and further biochemical analyses only with Congo red-staining of duodenal biopsy specimens. This will lead to the accumulation of cases and improve our understanding of AH amyloidosis.

Acknowledgment

The authors thank Mrs. Tomoko Nishizawa for technical assistance.

Abbreviations: GI, gastrointestinal; HE, hematoxylin and Eosin; Ig, immunoglobulin; LC-MS/MS, liquid chromatography-tandem mass spectrometry; LMD/MS, laser micro-dissection and mass spectrometry.

References

1. Manabe S, Hatano M, Yazaki M, Nitta K, Nagata M. Renal AH Amyloidosis Associated With a Truncated Immunoglobulin Heavy Chain Undetectable by Immunostaining. *Am. J. Kidney Dis.* 2015; **66**: 1095-1100.
2. Picken MM. Non-light-chain immunoglobulin amyloidosis: time to expand or refine the spectrum to include light+heavy chain amyloidosis? *Kidney Int.* 2013; **83**: 353-356.
3. Wechalekar AD, Gillmore JD, Hawkins PN. Systemic amyloidosis. *The Lancet* 2016; **387**: 2641-2654.
4. Eulitz M, Weiss DT, Solomon A. Immunoglobulin heavy-chain-associated amyloidosis. *Proc. Natl Acad. Sci. U S A* 1990; **87**: 6542-6546.
5. Solomon A, Weiss DT, Murphy C. Primary amyloidosis associated with a novel heavy-chain fragment (AH amyloidosis). *Am. J. Hematol.* 1994; **45**: 171-176.
6. Nasr SH, Lobritto SJ, Lauring BP, Arend LJ, D'Agati VD, Markowitz GS. A rare complication of monoclonal gammopathy. *Am. J. Kidney Dis.* 2002; **40**: 867-871.
7. Mai HL, Sheikh-Hamad D, Herrera GA, Gu X, Truong LD. Immunoglobulin heavy chain can be amyloidogenic: morphologic characterization including

immunoelectron microscopy. *Am. J. Surg. Pathol.* 2003; **27**: 541-545.

8. Copeland JN, Kouides PA, Grieff M, Nadasdy T. Metachronous development of nonamyloidogenic [lambda] light chain deposition disease and IgG heavy chain amyloidosis in the same patient. *Am. J. Surg. Pathol.* 2003; **27**: 1477-1482.

9. Yazaki M, Fushimi T, Tokuda T*, et al.* A patient with severe renal amyloidosis associated with an immunoglobulin gamma-heavy chain fragment. *Am. J. Kidney Dis.* 2004; **43**: e23-28.

10. Gono T, Yazaki M, Fushimi T*, et al.* AH amyloidosis associated with lymphoplasmacytic lymphoma secreting a monoclonal gamma heavy chain carrying an unusual truncated D segment. *Am. J. Kidney Dis.* 2006; **47**: 908-914.

11. Miyazaki D, Yazaki M, Gono T*, et al.* AH amyloidosis associated with an immunoglobulin heavy chain variable region (VH1) fragment: a case report. *Amyloid* 2008; **15**: 125-128.

12. Sethi S, Theis JD, Leung N*, et al.* Mass spectrometry-based proteomic diagnosis of renal immunoglobulin heavy chain amyloidosis. *Clin. J. Am. Soc. Nephrol.* 2010; **5**: 2180-2187.

13. Pradhan MA, Henderson RA, Patel D, McGhee CN, Vincent AL. Heavy-chain amyloidosis in TGFBI-negative and gelsolin-negative atypical lattice corneal

dystrophy. *Cornea* 2011; **30**: 1163-1166.

14. Nasr SH, Said SM, Valeri AM*, et al.* The diagnosis and characteristics of renal heavy-chain and heavy/light-chain amyloidosis and their comparison with renal light-chain amyloidosis. *Kidney Int.* 2013; **83**: 463-470.

15. Hassoun Y, Kharfan-Dabaja MA, Baz R. Bortezomib plus dexamethasone results in a late organ response in primary heavy-chain amyloidosis without a hematologic response. *Hematol. Oncol. Stem Cell Ther.* 2015; **8**: 138-139.

16. Hoshii Y, Setoguchi M, Iwata T*, et al.* Useful polyclonal antibodies against synthetic peptides corresponding to immunoglobulin light chain constant region for immunohistochemical detection of immunoglobulin light chain amyloidosis. *Pathol. Int.* 2001; **51**: 264-270.

17. Hoshii Y, Kiyama M, Cui D, Kawano H, Ishihara T. Immunohistochemical study of immunoglobulin light chain amyloidosis with antibodies to the immunoglobulin light chain variable region. *Pathol. Int.* 2006; **56**: 324-330.

18. Hoshii Y, Nanbara H, Cui D, Takahashi M, Ikeda E. Immunohistochemical examination of Aκ amyloidosis with antibody against adjacent portion of the carboxy terminus of immunoglobulin kappa light chain. *Med. Mol. Morphol.* 2012; **45**: 124-128.

19. van G, II, Hazenberg BP, Bijzet J, van Rijswijk MH. Diagnostic accuracy of subcutaneous abdominal fat tissue aspiration for detecting systemic amyloidosis and its utility in clinical practice. *Arthritis. Rheum.* 2006; **54**: 2015-2021.

20. Swan N, Skinner M, O'Hara CJ. Bone marrow core biopsy specimens in AL (primary) amyloidosis. A morphologic and immunohistochemical study of 100 cases. *Am. J. Clin. Pathol.* 2003; **120**: 610-616.

21. Tada S, Iida M, Iwashita A*, et al.* Endoscopic and biopsy findings of the upper digestive tract in patients with amyloidosis. *Gastrointest. Endosc.* 1990; **36**: 10-14.

22. Cowan AJ, Skinner M, Seldin DC*, et al.* Amyloidosis of the gastrointestinal tract: a 13-year, single-center, referral experience. *Haematologica* 2013; **98**: 141-146.

23. Said SM, Grogg KL, Smyrk TC. Gastric amyloidosis: clinicopathological correlations in 79 cases from a single institution. *Hum. Pathol.* 2015; **46**: 491-498.

24. Freudenthaler S, Hegenbart U, Schönland S , Behrens HM, Krüger S, Röcken C. Amyloid in biopsies of the gastrointestinal tract-a retrospective observational study on 542 patients. *Virchows Arch.* 2016; **468**: 569-577.

25. Desport E, Bridoux F, Sirac C*, et al.* Al amyloidosis. *Orphanet. J. Rare Dis.* 2012; **7**: 54.

26. Yazaki M, Ueno K, Katoh N *et al.* The first detailed postmortem pathological study of an AH amyloidosis patient who survived 17 years after the onset without any specific chemotherapies. *Proceedings of the XVth International Symposium on Amyloidosis*, 2016; **PC42**.

27. Matsuda M, Katoh N, Ikeda S. Clinical manifestations at diagnosis in Japanese patients with systemic AL amyloidosis: a retrospective study of 202 cases with a special attention to uncommon symptoms. *Intern Med.* 2014; **53**: 403-12.

28 Ravid M, Gafni J, Sohar E, Missmahl HP. Incidence and origin of non-systemic microdeposits of amyloid. *J Clin Pathol.* 1967; **20**: 15-20.

29 Tada S, Iida M, Yao T, *et al*. Endoscopic features in amyloidosis of the small intestine: clinical and morphologic differences between chemical types of amyloid protein. *Gastrointest Endosc.* 1994; **40**: 45-50.

Table 1. Amyloid deposition in duodenal biopsy specimens

Case	Lamina propria mucosa				Muscularis mucosae		Submucosa	
	Villus		Non-villus					
	CR	CRuP	CR	CRuP	CR	CRuP	CR	CRuP
AH 1	-	2+	-	2+	-	-	2+	3+
AH 2	+	3+	+	3+	2+	3+	3+	3+
AH 3	-	2+	+	3+	-	-	2+	3+
ALκ 1	-	-	-	-	3+	3+	4+	4+
ALκ 2	-	-	-	-	-	-	4+	4+
ALκ 3	-	-	3+	4+	4+	4+	4+	4+
ALκ 4	4+	4+	4+	4+	4+	4+	4+	4+
ALκ 5	-	-	-	-	3+	4+	4+	4+
ALκ 6	-	-	2+	3+	4+	4+	4+	4+
ALκ 7	-	-	3+	4+	4+	4+	4+	4+
ALκ 8	-	-	-	-	4+	4+	4+	4+
ALλ 1	-	-	-	-	-	-	3+	3+
ALλ 2	-	-	-	-	4+	4+	3+	4+
ALλ 3	-	-	-	-	3+	3+	4+	4+
ALλ 4	-	-	-	-	-	-	-	2+
ALλ 5	-	-	3+	4+	4+	4+	4+	4+
ALλ 6	-	-	-	-	4+	4+	4+	4+
ALλ 7	-	-	3+	4+	4+	4+	4+	4+
ALλ 8	-	-	-	-	4+	4+	4+	4+
ALλ 9	-	-	-	-	3+	3+	4+	4+
ALλ 10	-	-	-	-	3+	3+	4+	4+
ALλ 11	-	-	-	-	-	-	-	-
ALλ 12	-	-	3+	4+	4+	4+	4+	4+
ALλ 13	-	-	-	-	2+	2+	4+	4+

AH, immunoglobulin heavy chain amyloidosis; AL, immunoglobulin light chain amyloidosis; CR, Congo red staining; CRuP, Congo red staining observed under polarized light.

Table 2. Amyloid deposition in gastric biopsy specimens

Case	Lamina propria mucosae		Muscularis mucosae	
	CR	CRuP	CR	CRuP
AH 1	-	2+	-	+
AH 2	+	3+	+	+
AH 3	-	2+	-	-
ALκ 1	3+	4+	4+	4+
ALκ 2	-	-	-	-
ALκ 3	4+	4+	4+	4+
ALκ 4	4+	4+	4+	4+
ALκ 5	-	-	2+	2+
ALκ 6	4+	4+	4+	4+
ALκ 7	4+	4+	4+	4+
ALκ 8	+	+	4+	4+
ALλ 1	4+	4+	3+	4+
ALλ 2	-	-	4+	4+
ALλ 3	-	-	3+	3+
ALλ 4	-	2+	4+	4+
ALλ 5	4+	4+	4+	4+
ALλ 6	-	-	3+	3+
ALλ 7	4+	4+	4+	4+
ALλ 8	3+	4+	4+	4+
ALλ 9	-	-	3+	3+
ALλ 10	-	-	3+	3+
ALλ 11	-	2+	4+	4+
ALλ 12	4+	4+	4+	4+
ALλ 13	2+	3+	3+	4+

AH, immunoglobulin heavy chain amyloidosis; AL, immunoglobulin light chain amyloidosis; CR, Congo red staining; CRuP, Congo red staining observed under polarized light.

Figure legends

Figure 1. Duodenal biopsy specimens from a patient with immunoglobulin heavy chain (AH) amyloidosis and patients with immunoglobulin light chain (AL) amyloidosis.

Histopathological features of biopsy specimens. **(A-C)** AH amyloidosis patient 2 (AH 2), **(D-F)** ALκ amyloidosis patient 3 (ALκ 3) and **(G-I)** ALλ amyloidosis patient 5 (ALλ 5). Congo red staining in bright field observation (**A, D, G**) and Congo red staining observed under polarized light (**B, C, E, F, H, I**).

(**A**) Only a small amount of amyloid deposition is observed on the vessels in the submucosa (arrows). (**B**) In a lower magnification view (100x), fine and micro-granular birefringent deposition is observed mainly in the villi and submucosa (inset: higher magnification view of the amyloid deposition on a capillary wall located in between Brunner's glands), (**C**) Dotted line-like fine amyloid deposition is observed just beneath the epithelial basement membrane (arrows). (**D, E, G, H**) In contrast to AH amyloidosis, amyloid deposition of both types of AL amyloidosis is mainly observed in the muscularis mucosa and submucosa, and the deposition pattern is massive and diffuse. (**F, I**) No amyloid deposition is identified in the villi.

(**A, B, D, E, G, H**) Original magnification is 100x and scale bar is 250 μm. (**C, F, I**) Original magnification is 400x and scale bar is 50 μm.

Figure 2. Amyloid deposition in the duodenal villi in patients with immunoglobulin heavy chain (AH) amyloidosis.

Histopathological features of biopsy specimens. (**A-D**) AH amyloidosis patient 1 (AH 1), (**E-H**) AH 2 and (**I-L**) AH 3. Hematoxylin-eosin (HE) staining (**A, E, I**), Congo red staining under bright field observation (**B, F, J**), Congo red staining under polarized light (**C, G, K**), and immunohistochemistry for CD34 (**D, L**) and CD31 (**H**). **A-D**, **E-H** and **I-L** are serial sections, respectively.

(**A, E, I**) No obvious amyloid deposition is identified in the HE-stained sections. (**B, F, J**) Congo red positive deposition is not found in the villus. Only in AH 2, a small amount of amyloid deposition is recognizable on the wall of capillaries that contain erythrocytes (inset: higher magnification view of the capillaries indicated by arrow). (**C, G, K**) Dotted line-like deposition is observed just beneath the epithelial basement membrane of the villi (inset: higher magnification view of the dotted line-like deposition). (**D, H, L**) Capillaries are identified by immunostaining with antibodies against endothelial markers (CD31 or CD34) in the same sites of amyloid deposition (inset: higher magnification view of the capillaries indicated by arrow.

(**A-L**) Original magnification is 400x and scale bar is 50 μm.

Figure 3. Double immunostaining and Congo red staining of the duodenal villus in a patient with immunoglobulin heavy chain (AH) amyloidosis.

(**A-C**) Double staining with immunostaining for CD31 and Congo red staining, (**D-F**) double staining with immunostaining for type IV collagen and Congo red staining.

(**A, D**) No obvious amyloid deposition is identified in bright field observation. (**B, C, E, F**) Amyloid deposition is observed on the wall of capillaries under polarized light.

(**A, B, D, E**) Original magnification is 400x and scale bar is 50 μm, (**C, F**) Original magnification is 400x and scale bar is 25 μm.

Figure 4. Gastric biopsy specimens from a patient with immunoglobulin heavy chain (AH) amyloidosis and patients with immunoglobulin light chain (AL) amyloidosis.

Histopathological features of biopsy specimens. (**A, B**) AH amyloidosis patient 2 (AH 2), (**C, D**) ALκ amyloidosis patient 3 (ALκ 3) and (**E, F**) ALλ amyloidosis patient 5 (ALλ 3). Congo red staining observed in bright field (**A, C, E**) and under polarized light (**B, D, F**).

(**A**) No obvious amyloid deposition is observed. (**B**) Fine and focal amyloid deposition is faintly observed in the lamina propria mucosa. (Inset: higher magnification

view of the amyloid deposition in the lamina propria mucosa indicated by arrow). (**C-F**) Massive and diffuse deposition is observed in the stroma of lamina propria mucosa and muscularis mucosa.

(**A-F**) Original magnification is 100x and scale bar is 250 μm.

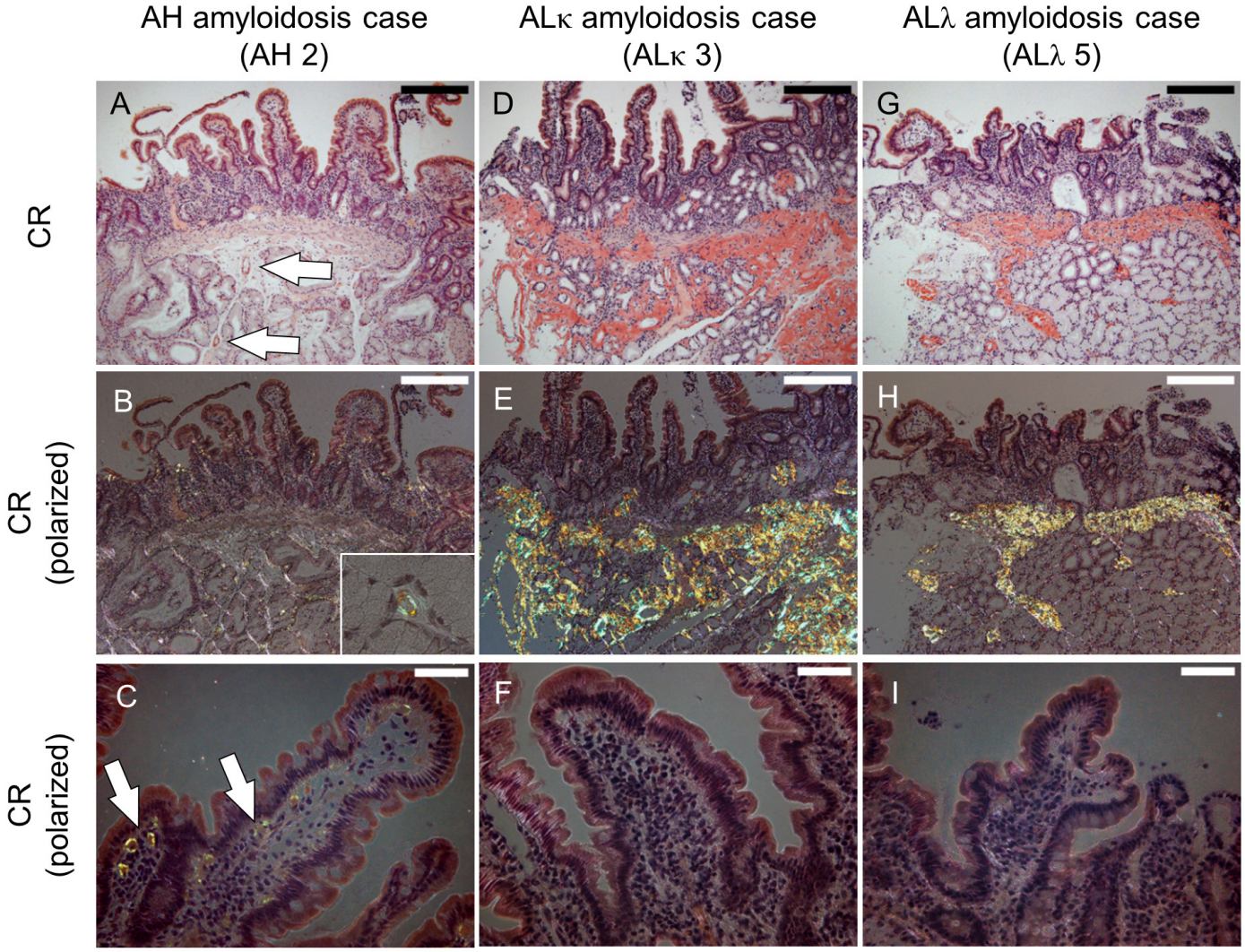
AH amyloidosis case
(AH 2)
ALκ amyloidosis case
(ALκ 3)
ALλ amyloidosis case
(ALλ 5)
CR
CR
(polarized)
CR
(polarized)
A
B
C
D
E
F
G
H
I

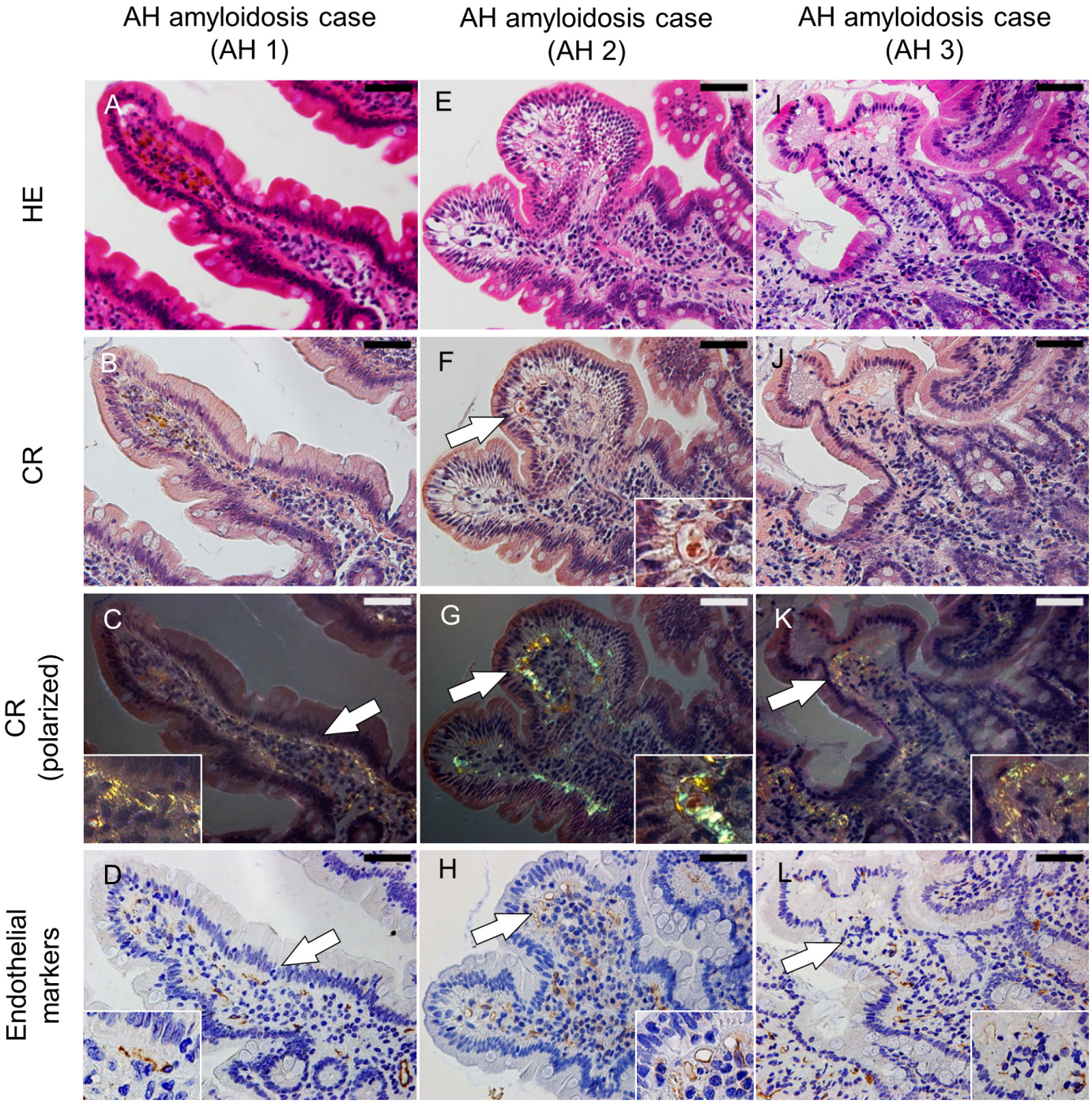
AH amyloidosis case
(AH 1)
AH amyloidosis case
(AH 2)
AH amyloidosis case
(AH 3)
HE
CR
CR
(polarized)
Endothelial
markers
A
E
I
B
F
J
C
G
K
D
H
L

Anti-CD31 antibodies
and Congo red

Anti-type IV collagen antibodies
and Congo red

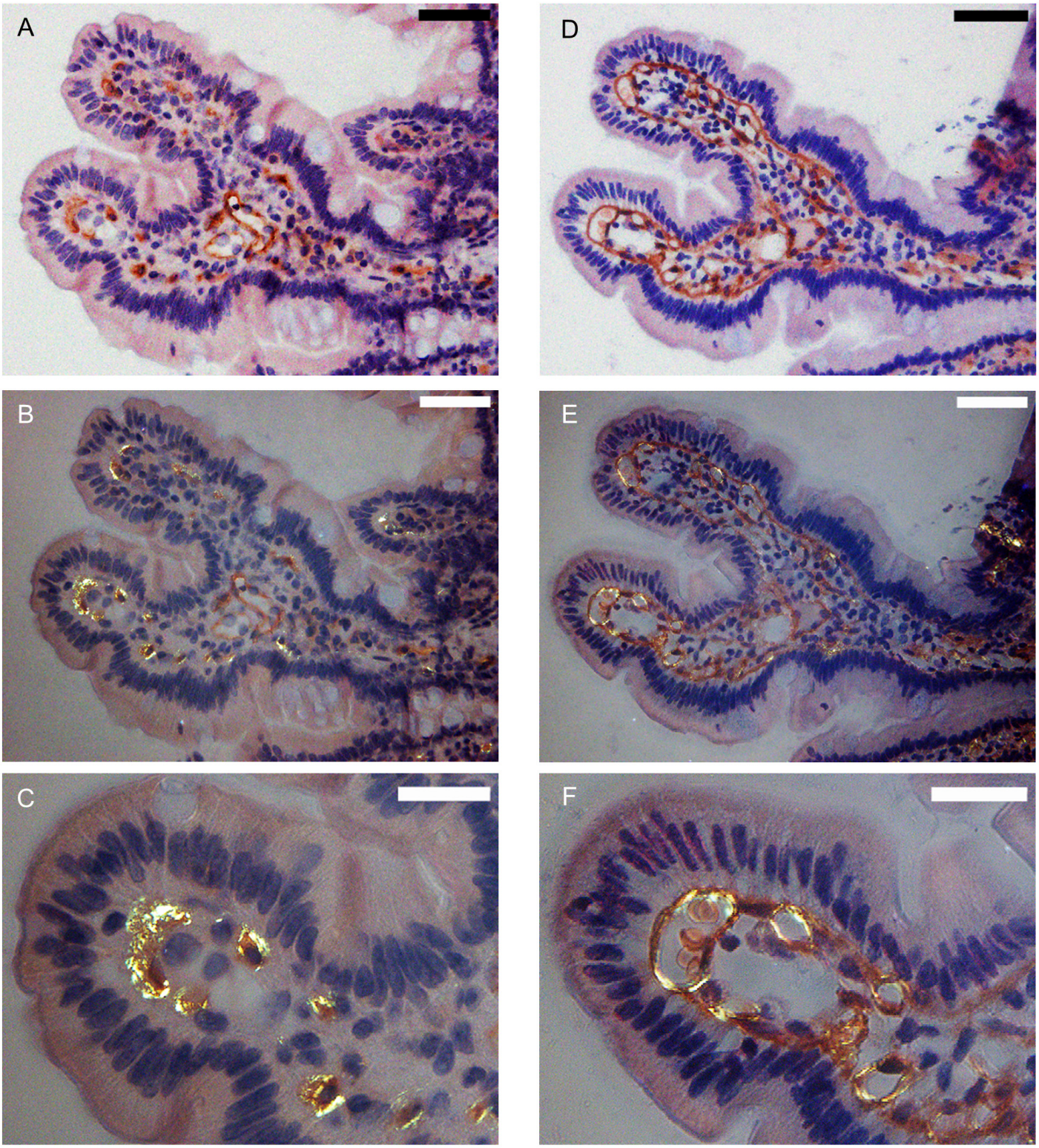

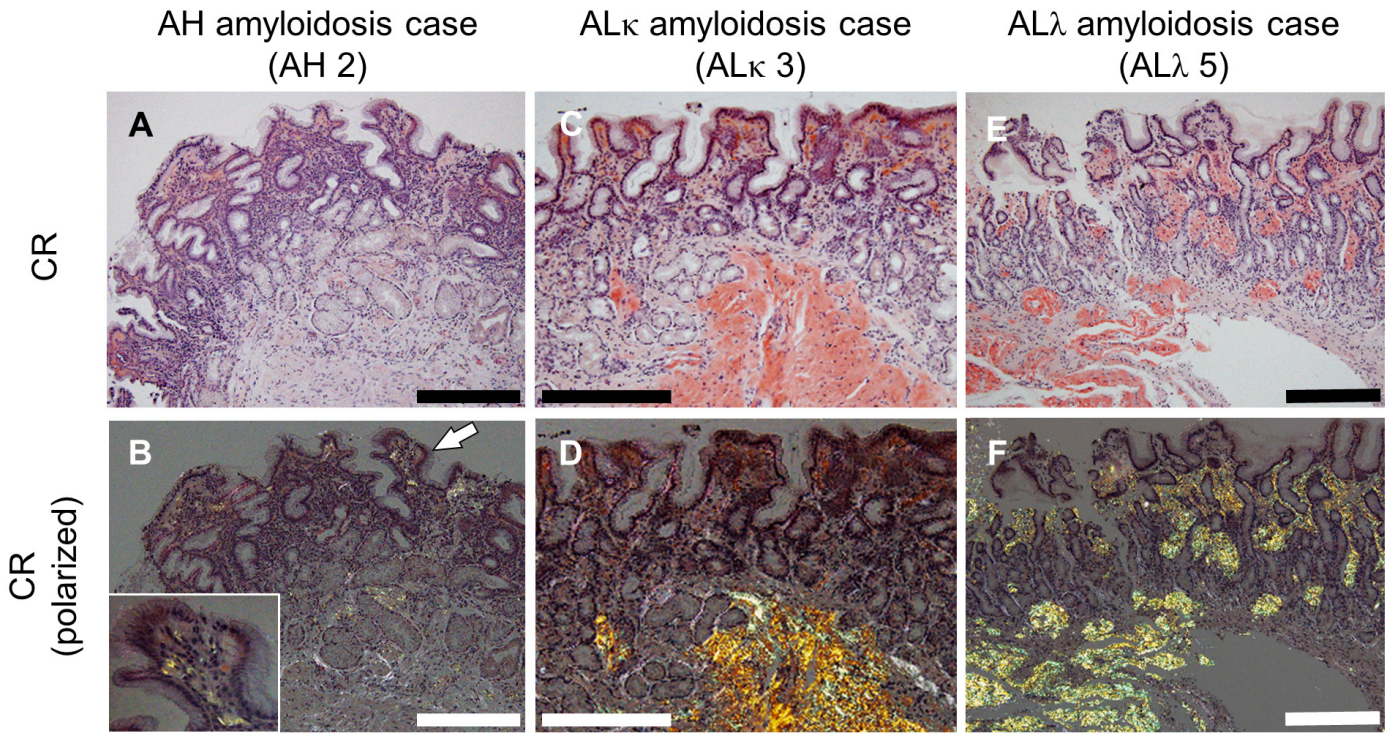
AH amyloidosis case
(AH 2)
ALκ amyloidosis case
(ALκ 3)
ALλ amyloidosis case
(ALλ 5)
CR
CR
(polarized)
A
B
C
D
E
F