

## A Case of Vaginal Varices that Caused Massive Bleeding after Vaginal Delivery

Norihiko KIKUCHI<sup>1)</sup>, Satoshi OHIRA<sup>1)</sup>, Ryoichi ASAKA<sup>1)</sup>  
Akiko TAKATSU<sup>1)</sup>, Hisanori KOBARA<sup>1)</sup>, Hirofumi ANDO<sup>1)</sup>  
Makoto KANAI<sup>2)</sup>, Tsutomu MIYAMOTO<sup>1)</sup> and Tanri SHIOZAWA<sup>1)\*</sup>

1) *Department of Obstetrics and Gynecology, Shinshu University School of Medicine*

2) *Department of Family and Child Nursing, and Midwifery, Shinshu University School of Health Sciences*

Vaginal varices are common during pregnancy and are rarely troublesome during the perinatal period. However, we report a woman who presented with massive postpartum hemorrhage caused by the rupture of prominent vaginal varices. A 35-year-old primigravida woman was found to have extensive vaginal varices with a red color on the surface at 28 weeks of gestation. She delivered a healthy infant at term. Immediately after the delivery, massive hemorrhage from the torn varices occurred. We first tried surgical sutures, but bleeding points could not be clearly identified because of the massive hemorrhage. We performed vaginal gauze packing to reduce the bleeding. The estimated blood loss at delivery was 3,770 ml. Two days after the delivery we removed the vaginal packing, but massive hemorrhage from the varices resumed immediately. The blood loss was approximately 2,000 ml in a few minutes, and the vaginal packing was the only means to control the bleeding. Both seven and 21 days after the delivery, balloon occlusion of the bilateral common iliac arteries was performed, but sufficient hemostasis was not achieved and vaginal packing was performed again. Because vaginal hemorrhage slowly decreased during the packing, we started step-wise removal of the vaginal packing and performed complete removal on the 48th day of puerperium without notable hemorrhage. Although life-threatening postpartum hemorrhage caused by vaginal varices is very rare, the present case suggests the need for an appropriate indication to avoid vaginal delivery. *Shinshu Med J 64 : 35–39, 2016*

(Received for publication September 24, 2015 ; accepted in revised form November 19, 2015)

---

**Key words :** vaginal varices, massive postpartum hemorrhage, vaginal packing

---

### I Introduction

Varicose veins during pregnancy are common, affecting up to 15 % of the population<sup>1)</sup>. In particular, perineal and vaginal varices during pregnancy are very common and usually do not lead to life-threatening obstetric hemorrhage. Therefore, vaginal varices generally are not an indication for cesarean section. However, when large vaginal varices

such as those extending to the vaginal fornix rupture and massive hemorrhage occurs, surgical hemostasis is very difficult. We report a case of varices associated with massive bleeding after vaginal delivery, for which vaginal packing was the most effective.

### II Case Report

A 35-year-old primigravida woman with no complications visited our hospital at 11 weeks of gestation for routine prenatal care. At 28 weeks of gestation, vaginal examination revealed extensive vaginal varices with a red color on the surface (**Fig. 1**). There was no complaint such as abnormal bleed-

---

\* Corresponding author : Tanri Shiozawa  
Department of Obstetrics and Gynecology, Shinshu University School of Medicine, 3-1-1 Asahi, Matsumoto, Nagano 390-8621, Japan  
E-mail : tanri@shinshu-u.ac.jp

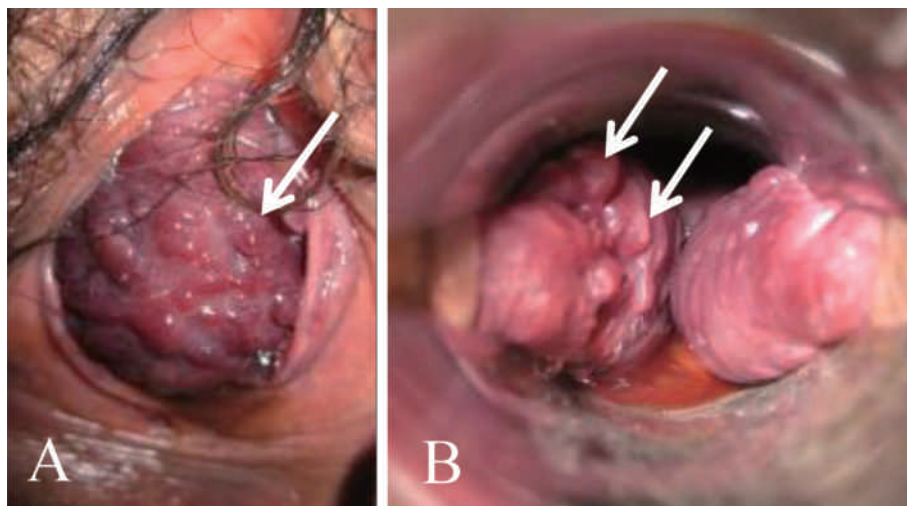


Fig. 1 At 28 weeks of gestation, vaginal examination revealed extensive vaginal varices with a red color on the surface (arrows).  
A : vaginal introitus. B : inspection by vaginal speculum.

ing or pain until term. After the onset of labor, the progress of delivery was uneventful, and a 2,562-g male infant was delivered at 39 weeks of gestation. After the placenta was delivered, massive vaginal bleeding was noted. Because uterine contraction was sufficient, the bleeding was considered to have originated from the vaginal cavity. We then identified multiple bleeding sites from the vaginal varices. We first tried surgical sutures, but hemostasis was impossible because of the bloody, limited operative field and friable vaginal wall. During the massive vaginal bleeding, her blood pressure was 64/35 mmHg, and pulse was 168/min. Therefore, vaginal packing using approximately 30 pieces of gauze containing povidone iodine was performed, and the bleeding was reduced. At this point in time, only conservative management was effective. After vaginal packing and blood transfusion, the blood pressure stabilized at 100-120/60-70 mmHg. Total blood loss was 3,770 ml. The prophylactic antibiotic Cefmetazole sodium was administered at a daily dose of 3 g.

Two days after the vaginal delivery, the vaginal packing was removed since natural hemostasis was expected. However, as soon as the packing was removed, massive vaginal hemorrhage resumed. The estimated blood loss this time was as much as 2,000 ml within five minutes after the removal.

Because multiple bleeding sites could be roughly identified this time, surgical suture was attempted. However, a large amount of bleeding and the vulnerable vaginal wall hampered observation and suturing (**Fig. 2**). Therefore, gauze packing with the use of tissue-adhesive sheets containing fibrinogen was performed again, and the bleeding markedly reduced. Although the patient temporarily developed disseminated intravascular coagulation due to the total blood loss of 3,200 ml, this was improved by blood transfusion including fresh frozen plasma and platelet concentrate.

At both seven and 21 days after the vaginal delivery, the vaginal packing was removed. Before the removal, interventional radiology, involving balloon occlusion of the bilateral common iliac artery, was performed on both days. Just after the removal of the gauze, a moderate amount of bleeding was observed. Surgical suture of the bleeding points was possible up to the middle of the vaginal cavity, but the suture of deeper sites near the vaginal fornix was impossible. Gauze packing was again performed and the bleeding stopped. This gauze contained terramycin ointment instead of povidone iodine, because povidone iodine became dry and adherent to the vaginal mucosa.

As a result of these attempts, we considered that vaginal packing was the most effective. The amount

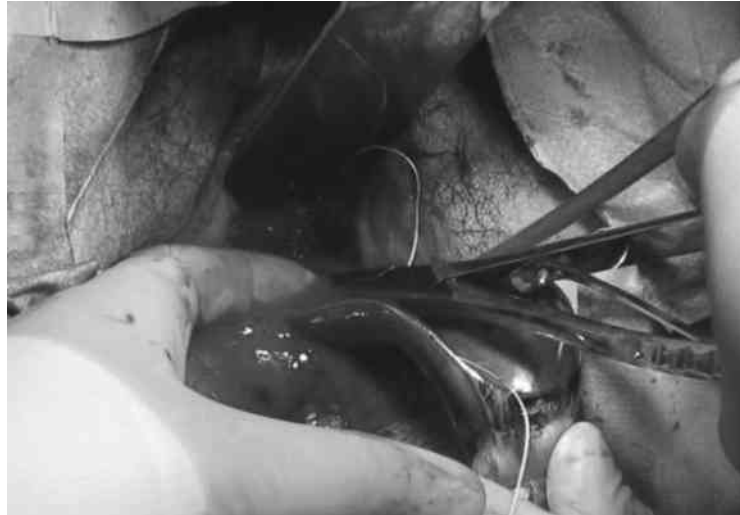

Fig. 2 A large amount of vaginal bleeding and vulnerable vaginal wall hamper observation and suturing.

of bleeding and number of pieces of gauze necessary for hemostasis were reduced on each subsequent hemostatic procedure. This was possibly due to a reduced blood supply around the vagina in association with involution of the uterus.

From thirty-one days after the vaginal delivery, vaginal packing was gradually removed every day. Seventeen days later, the vaginal packing had been removed completely and the patient was discharged on the fifty-seventh postpartum day. At 18 months after childbirth, the vaginal wall was macroscopically normal without apparent varices.

### III Discussion

Perineal and/or vaginal varices during pregnancy are very common. The physical changes that have been proposed as contributing to the development of varices during pregnancy include: 1) venous distension due to plasma volume expansion; 2) hormonal changes; 3) increased intra-abdominal pressure; and 4) compression of the inferior vena cava and pelvic veins by the pregnant uterus<sup>2)</sup>. Vaginal varices are usually not a cause of life-threatening postpartum hemorrhage. Therefore, unless it is a special case such as Klippel-Trenaunay syndrome which is characterized by capillary and venous malformations<sup>3)</sup>, they are generally not an indication for a cesarean section. Furuta et al.<sup>4)</sup> reported

a case of successful vaginal birth with huge vulvar and vaginal varicosities. They suggested that women with vulvar varicosities could be allowed to attempt a vaginal birth regardless of their severity because varicose veins become compressed by the fetal head from the inside and markedly diminish in size during crowning and after delivery<sup>4)</sup>. Meanwhile, in an earlier reported case with extensive varices of the vulva and vagina<sup>5)</sup>, an elective cesarean section was performed for fear of their rupture during a vaginal delivery. In fact, we found no report in the literature of massive postpartum hemorrhage due to the rupture of vaginal varices.

In the present case, surgical hemostasis, i.e., banding hemostasis of bleeding sites, was difficult because marked, continuous bleeding impaired the visual field. Bleeding points were multiple and located at various sites in the vaginal wall, including near the vaginal fornix. In addition, most of the vaginal wall was occupied by lacerated varices after vaginal delivery, and the mucosa was excessively friable for suturing. Embolization of the common iliac artery was not effective, because an active bleeding point on an arteriogram could not be detected and the main source of bleeding was a vein.

In this case, we concluded that compression was the most effective for hemostasis. Because the pelvic veins and inferior vena cava were compressed

by the enlarging pregnant uterus, vascular dilatation and increased venous pressure may have been contributing factors in the development of vaginal varices. We considered that blood flow around the vagina would decrease with involution of the uterus.

During the gauze tamponade, the risk of infection, delayed wound healing due to decreased blood supply, and the formation of a recto-vaginal or vesico-vaginal fistula were matters of concern. However, infection was not observed. Although the reason is unknown, the use of gauze containing povidone iodine or the antibiotic tetracycline was effective. Wound healing might have been delayed; however, precise evaluation is difficult because of the lack of an appropriate comparison. Fortunately, fistula formation did not occur, possibly because of sufficient blood supply even in the presence of compression. We believe that the use of a tissue-adhesive sheet alleviated the hemostasis and promoted wound healing, but precise evaluation of the effectiveness was difficult due to the lack of an appropriate control.

Recently, several reports have documented the use of recombinant activated factor VII (rFVIIa) in cases of life-threatening postpartum hemorrhage<sup>6)7)</sup>. Because the bleeding source was mainly a vein in this case, rFVIIa may have been effective. However, rFVIIa may induce a thrombus as a serious side

effect<sup>8)</sup> in such a case with effective vaginal packing; we therefore did not use it.

Evaluation of a hemorrhagic varicose vein is difficult. This case suggests that not only the size of varices but also the color may be important. Varicose veins of the vagina or perineum are usually blue-purple in color, but they looked red in this case. In esophageal varices, the color of the surface of varicose veins is indicative of bleeding; a red color signifies a state in which the small blood vessels have been extended, suggesting the risk of bleeding<sup>9)</sup>. Moreover, in the above-mentioned case in which an elective cesarean section was performed, the author stated that the vaginal varix assumed 'a port-wine color'<sup>5)</sup>. We consider that the criterion of color in esophageal varices may be applicable to vaginal varices.

In conclusion, we encountered a patient with ruptured extensive vaginal varices which caused massive postpartum hemorrhage. Gauze packing was the only effective treatment. Vaginal delivery should be avoided in the case of large vaginal varices with a red-colored surface.

#### Disclosure Statement

The authors have no potential conflicts of interest associated with this case report.

#### References

- 1) Evans CJ, Allan PL, Lee AJ, Bradbury AW, Ruckley CV, Fowkes FG : Prevalence of venous reflux in the general population on duplex scanning : The Edinburgh vein study. *J Vasc Surg* 28 : 767-776, 1998
- 2) Kusanovic JP, Soto E, Espinoza J, Stites S, Gonçalves LF, Santolaya J, Nien JK, Erez O, Sorokin Y, Romero R : Cervical varix as a cause of vaginal bleeding during pregnancy-prenatal diagnosis by color Doppler ultrasound. *J Ultrasound Med* 25 : 545-549, 2006
- 3) Torres-Farias E, Torres-Gómez LG, Burciaga-Sepúlveda AS : Klippel-Trenaunay syndrome and pregnancy. Case report. *Ginecol Obstet Mex* 78 : 287-290, 2010
- 4) Furuta N, Kondoh E, Yamada S, Kawasaki K, Ueda A, Mogami H, Konishi I : Vaginal delivery in the presence of huge vulvar varicosities : a case report with MRI evaluation. *Eur J Obstet Gynecol Reprod Biol* 167 : 127-131, 2013
- 5) Adler SS : Extensive varix of vulva and vagina in full-term pregnancy ; delivery by cesarean section. *Am J Obstet Gynecol* 51 : 272-274, 1946
- 6) Karalpillai D, Popham P : Recombinant factor VIIa in massive postpartum haemorrhage. *Int J Obstet Anesth* 16 : 29-34, 2007

Massive postpartum hemorrhage due to vaginal varices

- 7) Ahonen J, Jokela R, Korttila K : An open non-randomized study of recombinant activated factor VII in major postpartum haemorrhage. *Acta Anaesthesiol Scand* 51 : 929-936, 2007
- 8) O'Connell KA, Wood JJ, Wise RP, Lozier JN, Braun MM : Thromboembolic adverse events after use of recombinant human coagulation factor VIIa. *JAMA* 295 : 293-298, 2006
- 9) Ichikawa S, Okamura S, Tujigaki K, Kusaka Y, Tadatsu M, Okita Y, Tsutsui A, Muguruma N, Okahisa T, Shibata H, Shimizu I, Ito S, Umino K : Quantitative analysis of red color sign in the endoscopic evaluation of esophageal varices. *Endoscopy* 33 : 747-753, 2001

(2015. 9. 24 received ; 2015. 11. 19 accepted)

---