

**Penetration of the Optic Nerve or Chiasm by  
Anterior Communicating Artery Aneurysms.  
- Three Case Reports-**

Tetsuyoshi Horiuchi<sup>1</sup>, Toshiya Uchiyama<sup>1</sup>, Yoshikazu Kusano<sup>1</sup>,  
Maki Okada<sup>1</sup>, Kazuhiro Hongo<sup>1</sup>, and Shigeaki Kobayashi<sup>2</sup>

<sup>1</sup>Department of Neurosurgery,  
Shinshu University School of Medicine, Matsumoto, Nagano, Japan

<sup>2</sup>Department of Neurosurgery,  
Aizawa Hospital, Matsumoto, Nagano, Japan

**Key words:** aneurysm, anterior communicating artery, optic chiasm, optic nerve, penetration

**Running head:** Penetration of optic nerve or chiasm

Correspondence to:

Tetsuyoshi Horiuchi, M.D.

Department of Neurosurgery,

Shinshu University School of Medicine,

3-1-1 Asahi, Matsumoto, 390-8621 (postal code), Japan

Telephone: +81-263-37-2690

Fax: +81-263-37-0480

E-mail: [tetuyosi@shinshu-u.ac.jp](mailto:tetuyosi@shinshu-u.ac.jp)

**Abstract**

Although large and giant aneurysms can induce visual disturbance by compression of the anterior visual pathway, splitting and penetration of the optic apparatus are extremely rare. The authors describe 3 patients who underwent clipping surgery for the anterior communicating artery aneurysm infiltrating into the optic nerve or chiasm. These findings were suspected on the preoperative magnetic resonance imaging and confirmed at surgery. Two aneurysms were ruptured and one unruptured. We review the literature and discuss the mechanism of cranial nerve penetration by an aneurysm.

## Introduction

Since cerebral aneurysms of the internal carotid artery (ICA) and the anterior communicating artery (ACoA) are located closely to the optic nerve and chiasm, some of them can compress the anterior visual pathway causing visual disturbance.<sup>3, 10)</sup> However, its penetration and splitting by a cerebral aneurysm is rare. Hongo et al.<sup>5)</sup> first reported in 1981, a case of the right ICA aneurysm that penetrated and split the optic chiasm. To our knowledge, there have been only 8 cases reporting penetration and splitting of the optic nerve or chiasm by ICA<sup>1, 4, 5, 7, 8, 11)</sup> or ACoA aneurysms.<sup>2, 9)</sup> We recently encountered a case (Case 3) with the penetration of optic chiasm by the unruptured ACoA aneurysm. Therefore, similar cases were retrospectively searched using the operation records written by senior authors (K.H. and S.K.). Additional 2 cases were found. Here, we describe total 3 cases of ACoA aneurysm penetrating the anterior visual pathway and review the literature.

## Case report

### Case 1

**History and Examination.** This 62-year-old man presented with sudden onset of headache. His neurological examination revealed no abnormalities. He did not complain visual disturbances. Computed tomography (CT) demonstrated subarachnoid hemorrhage (SAH) and cerebral angiography detected an ACoA aneurysm (Figure 1). Since the emergency surgery was needed to prevent the re-rupture, no detailed ophthalmological evaluations were performed.

**Operation and Postoperative Course.** A right pterional approach was used and the aneurysm was found impinging upon the right optic nerve (Figure 1). It was not fully dissected from

the optic nerve not to damage the nerve. This impingement was verified by the senior author's operative reports. A straight clip was applied for obliteration. The patient tolerated the procedure well and was discharged without neurological deficits.

### Case 2

**History and Examination.** This 53-year-old man presented to a near-by hospital with one-month history of difficulty seeing with the right eye and intermittent severe headaches. His visual acuity was 20/20 in both eyes. The nasal hemianopia of the right eye was detected on Goldmann visual field examination (Figure 2-1). CT and magnetic resonance imaging (MRI) revealed a mass in the right prechiasmal region (Figure 2-2). The patient was referred to us. Angiogram showed an ACoA aneurysm (Figure 2-2).

**Operation and Postoperative Course.** A fronto-temporal craniotomy was performed and transsylvian approach was used. There was an evidence of recent SAH. A red mark was seen on the optic nerve just distal to the optic canal; this was suspectedly caused by the hemorrhage. The aneurysmal dome was located inside the right optic nerve (Figure 2-2). The aneurysm was successfully clipped with a bayonet clip and punctured for decompression. Postoperative course was uneventful. His visual acuity was unchanged. The nasal hemianopia of the right eye improved after surgery (Figure 2-3). Follow-up angiogram showed complete obliteration of the aneurysm.

### Case 3

**History and Examination.** This 65-year-old woman was diagnosed as having multiple cerebral aneurysms on brain check-up. Cerebral angiogram demonstrated aneurysms in the bilateral middle cerebral arteries, right superior cerebellar artery, and ACoA. The ACoA aneurysm was irregular in shape with bleb and infiltrated the optic chiasm on MRI (Figure 3).

Preoperatively, her visual acuity was 20/20 in both eyes and no visual field defect was detected.

**Operation and Postoperative Course.** Under general anesthesia, the ACoA and left middle cerebral artery aneurysms were exposed through an ordinary left pterional route. The ACoA aneurysm was tightly embedded in the optic chiasm (Figure 4). The aneurysm dome was carefully dissected away from the chiasm. Neither tiny artery nor hemosiderin deposit suggesting the previous hemorrhage were seen in the penetrated chiasm. The 2 unruptured aneurysms were clipped successfully. The ACoA aneurysm was punctured to confirm complete occlusion and for decompression. No visual disturbance occurred after surgery and she was discharged in good condition.

### **Discussion**

In the present study, we reported 3 cases of ACoA aneurysms penetrating the optic nerve and chiasm. Cerebral aneurysms arising from the circle of Willis are located closely to cranial nerves such as optic and oculomotor nerves.<sup>3, 10)</sup> Therefore, aneurysms can produce compression of these nerves causing their dysfunction. However, penetration, splitting, or fenestration of cranial nerves by aneurysms is extremely rare.<sup>6)</sup> Table 1 summarizes clinical characteristics of 8 reported aneurysms penetrating optic nerve or chiasm and the 3 present cases. There are 6 ICA and 5 ACoA aneurysms. In 7 of these cases, the patients presented with an aneurysmal rupture.

The mean age of ACoA aneurysm patients is 55years with male preponderance. By contrast, sex distribution is opposite in ICA aneurysms. The ACoA aneurysm size (mean: 6.5 mm) is smaller than the ICA (18.1 mm). In 3 of the 5 ACoA cases, the patients presented with aneurysmal rupture and preoperative visual symptoms in 2 patients were suspected to be caused by bleeding in the anterior visual pathway and not by compression.

In the previously reported case by Date et al.,<sup>2</sup> the visual disturbance including filed defects and decreased acuity did not improve after clipping surgery, while unilateral hemianopia recovered well in the present Case 2. There are 3 possibilities to explain this difference. First, visual field is more likely to improve than visual acuity.<sup>3)</sup> Second, this difference might depend on the initial damage to the visual pathway by aneurysmal rupture. Third, the aneurysm of Case 2 was well decompressed by the puncture because the aneurysm was a saccular type. By contrast, the aneurysm in Date's case<sup>2)</sup> was partially thrombosed and the thrombosed part of the aneurysm remained in the right optic nerve after clipping. No deterioration of visual function occurred after the surgery in the reported cases.

There are several mechanisms to explain penetration or splitting of the optic nerve and chiasm by cerebral aneurysm.<sup>1)</sup> Previously, we reported a case in which the oculomotor nerve was split by ICA-posterior communicating artery aneurysm.<sup>6)</sup> We speculated that a sentinel hemorrhage caused a rent in the nerve and subsequent growth of the aneurysm resulted in mechanical fenestration. This speculation was applicable to the present Case 2 according to the history and operative findings. By contrast, in the Case 1 and 3, there were no visual disturbances although the aneurysms tightly infiltrated the nerve and the chiasm, respectively. Other two possibilities causing the fenestration were growth of the aneurysm along the congenital splitting of the nerve, enlarging through the perforating artery of the nerve.<sup>6)</sup> Based upon intraoperative findings of the Case 3, the aneurysm actually penetrated without congenital splitting and perforating artery. In Case 1, no dissection was performed between the nerve and the aneurysm not to injure the nerve. Therefore, neither congenital splitting nor perforating artery could be confirmed. Fujita and colleagues<sup>4)</sup> proposed that the rapid ICA aneurysm growth without rupture induced visual symptoms and fenestration of the optic chiasm by allowing the aneurysm to infiltrate the tightly bound fibers of the optic nerve. By contrast, in the absence of visual disturbance, Jea et al.<sup>7)</sup> speculated

that the aneurysm grew slowly and parted the nerve because the unruptured aneurysm did not usually have the potentially aggressive behavior as proposed by Fujita and colleagues.<sup>7)</sup> Therefore, it is possible that the local aneurysmal arterial pulsation can create the gap between fibers of the chiasm without causing rupture and penetrate the nerve as observed in the present Case 3. Additionally, anatomical relationship between the anterior visual pathway and surrounding structures might support its hypothesis because the optic nerve is anchored with the chiasm and the optic canal, and likewise the chiasm with the nerve and the optic tract. Therefore, the small unruptured pulsatile aneurysm can chronically exert local compression to the anterior visual pathway resulting in penetration along the nerve fibers. We propose that the unruptured ACoA aneurysm protruding inferiorly should be evaluated carefully to exclude a penetration of the optic nerve and chiasm by preoperative MR imagings.

We reported new 3 cases of ruptured and unruptured ACoA aneurysms infiltrating the anterior visual pathway. The mechanism of fenestration would be different between ruptured and unruptured aneurysms. Further accumulation of similar cases will be necessary to prove the exact mechanism of the optic nerve and chiasm fenestration.

## Reference List

- 1) Beatty RA: Splitting of the optic nerve by a carotid-ophthalmic artery aneurysm. Case report. *J Neurosurg* **65**:560-562, 1986
- 2) Date I, Akioka T, Ohmoto T: Penetration of the optic chiasm by a ruptured anterior communicating artery aneurysm. Case report. *J Neurosurg* **87**:324-326, 1997
- 3) Date I, Asari S, Ohmoto T: Cerebral aneurysms causing visual symptoms: their features and surgical outcome. *Clin Neurol Neurosurg* **100**:259-267, 1998
- 4) Fujita A, Tamaki N, Yasuo K, Nagashima T, Ehara K: Complete penetration of the optic chiasm by an unruptured aneurysm of the ophthalmic segment: case report. *Surg Neurol* **57**:130-134, 2002
- 5) Hongo K, Kobayashi S, Inoue T, Hara H, Ohigashi Y, Sugita K: Two cases of the posterior chiasmal lesion with interesting intraoperative findings. *Gannka Rinsyo Iho* **75**:900-903, 1981
- 6) Horiuchi T, Kyoshima K, Oya F, Kobayashi S: Fenestrated oculomotor nerve caused by internal carotid-posterior communicating artery aneurysm: case report. *Neurosurgery* **40**:397-398, 1997
- 7) Jea A, Baskaya MK, Morcos JJ: Penetration of the optic nerve by an internal carotid artery-ophthalmic artery aneurysm: case report and literature review. *Neurosurgery* **53**:996-999, 2003
- 8) Kanamaru K, Ishida F, Taki W: Splitting and penetration of the optic nerve by an



- aneurysm arising from the anterior wall of internal carotid artery: case report. *J Neurol Neurosurg Psychiatry* **71**:525-527, 2001
- 9) Kuzu Y, Ogasawara K, Kikuchi Y, Ogawa A: Splitting and penetration of the optic nerve by an unruptured aneurysm arising from the anterior communicating artery. *Jpn J Neurosurg* **13**:605-607, 2004
- 10) Nonaka T, Haraguchi K, Baba T, Koyanagi I, Houkin K: Clinical manifestations and surgical results for paraclinoid cerebral aneurysms presenting with visual symptoms. *Surg Neurol* **67**:612-619, 2007
- 11) Sato T, Sasaki T, Sakuma J, Suzuki K, Matsumoto M, Sato M, Itakura T, Kodama N: [Case of ruptured carotid-ophthalmic aneurysm splitting the optic nerve]. *No Shinkei Geka* **37**:375-380, 2009

### Figure legends

Figure 1: Case 1. A: Oblique projection of the right carotid artery injection revealing a 5-mm saccular aneurysm (arrow) projecting inferiorly at the anterior communicating artery (ACoA). B: Intraoperative drawing showing the aneurysm (arrow) infiltrating the right optic nerve. Asterisk indicating the ACoA.

Figure 2-1: Case 2. Preoperative Goldmann perimetry showing the nasal hemianopia of the right eye.

Figure 2-2: Coronal (A) and sagittal (B) MR images showing a signal flow void representing the anterior communicating artery aneurysm (arrow) within the right optic nerve. Oblique view of right carotid angiogram (C) showing a 9-mm ACoA aneurysm (arrow) projecting infero-laterally. Intraoperative drawing through the right pterional approach (D) demonstrating the aneurysm (arrow) infiltrating the right optic nerve.

Figure 2-3: Postoperative Goldmann perimetry showing the improvement of the nasal hemianopia of the right eye.

Figure 3: Case 3. Anteroposterior projection of left carotid artery injection (A) showing a 5-mm ACoA aneurysm (arrow). Coronal section of MR images (B) demonstrating the chiasm penetrated by the aneurysm (arrow). Three-dimensional computed tomography angiography (C) revealing the aneurysm (arrow) with bleb projecting inferiorly.

Figure 4: Case 3. Intraoperative photographs (A: before clipping, B: during dissection, C: after clipping) showing the aneurysm protruding inferiorly. Note that the aneurysm

infiltrates the chiasm tightly (arrow and asterisk) and there are no perforating artery and no evidence of rupture.

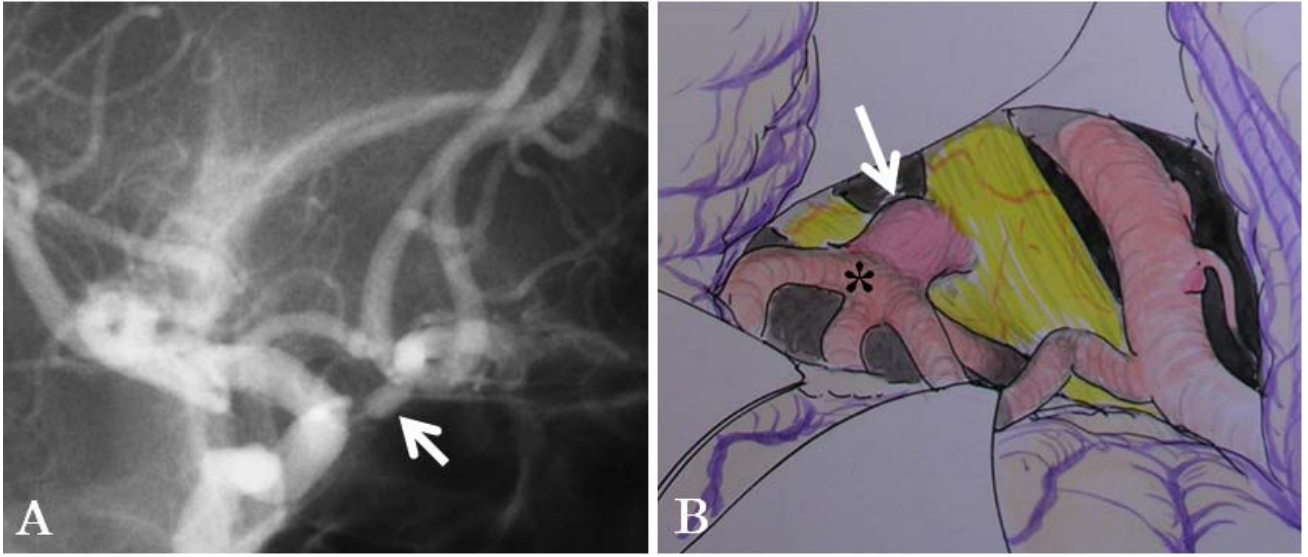


Figure 1

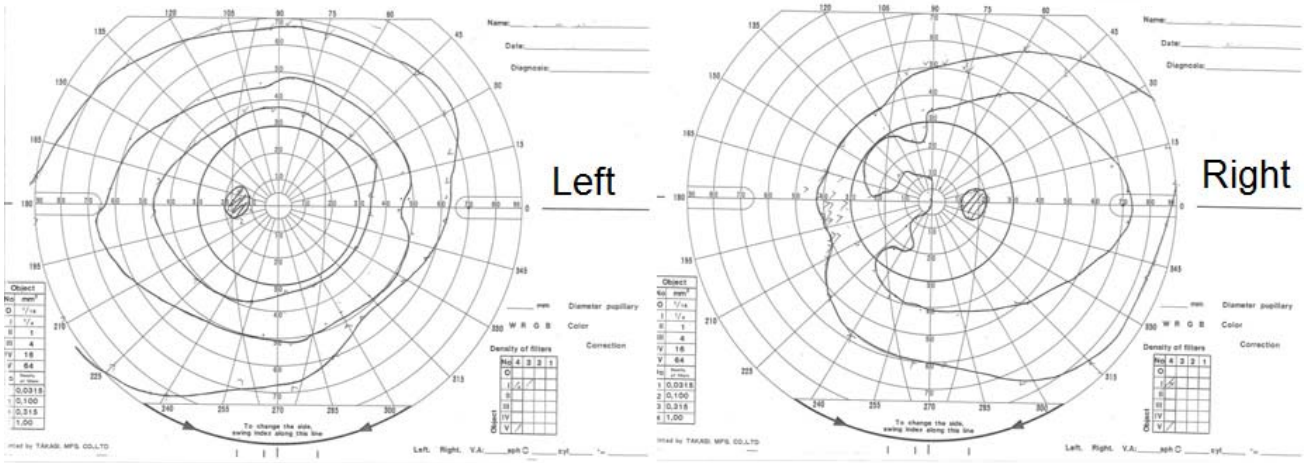


Figure 2-1

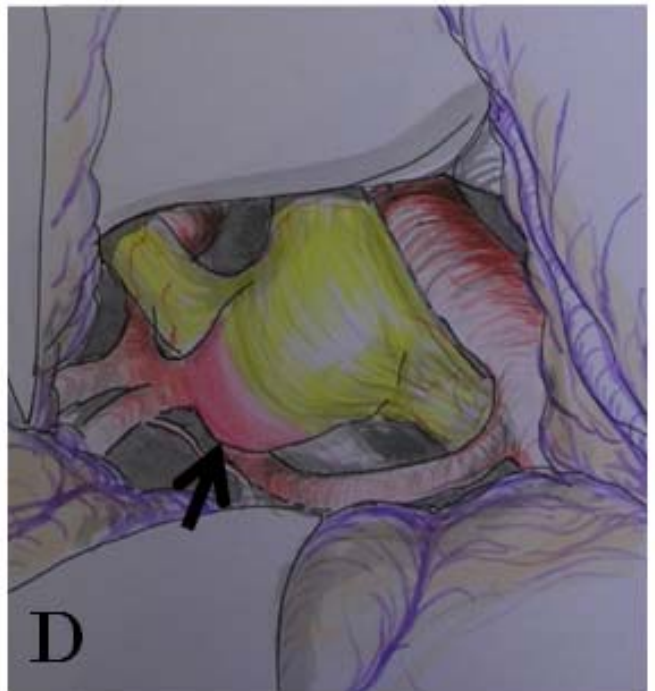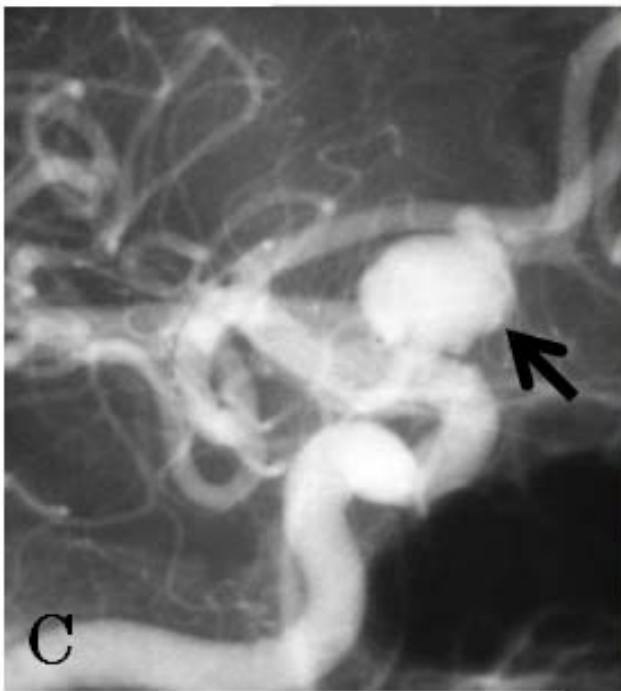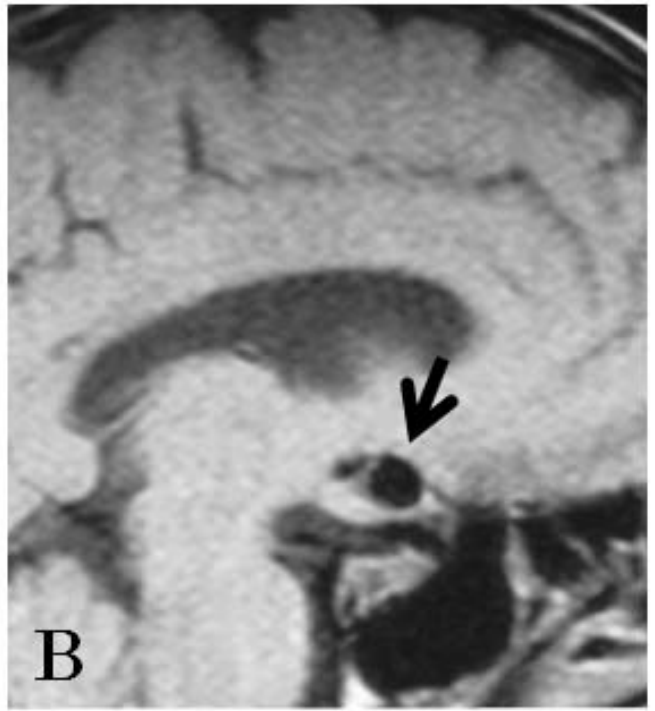
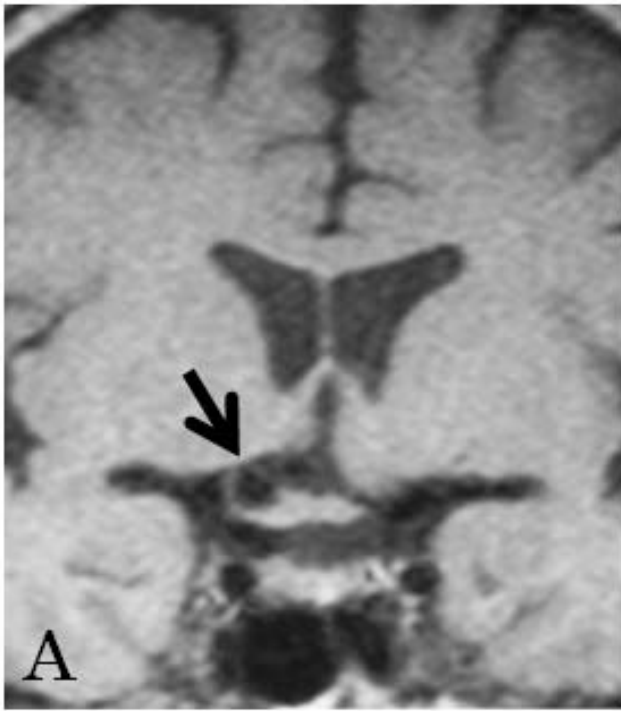


Figure 2-2

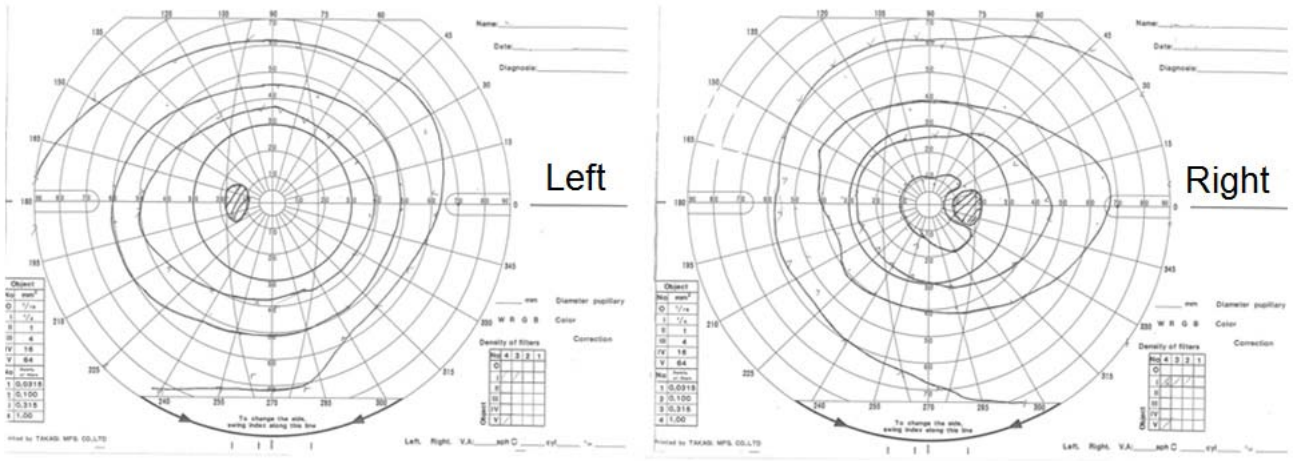


Figure 2-3

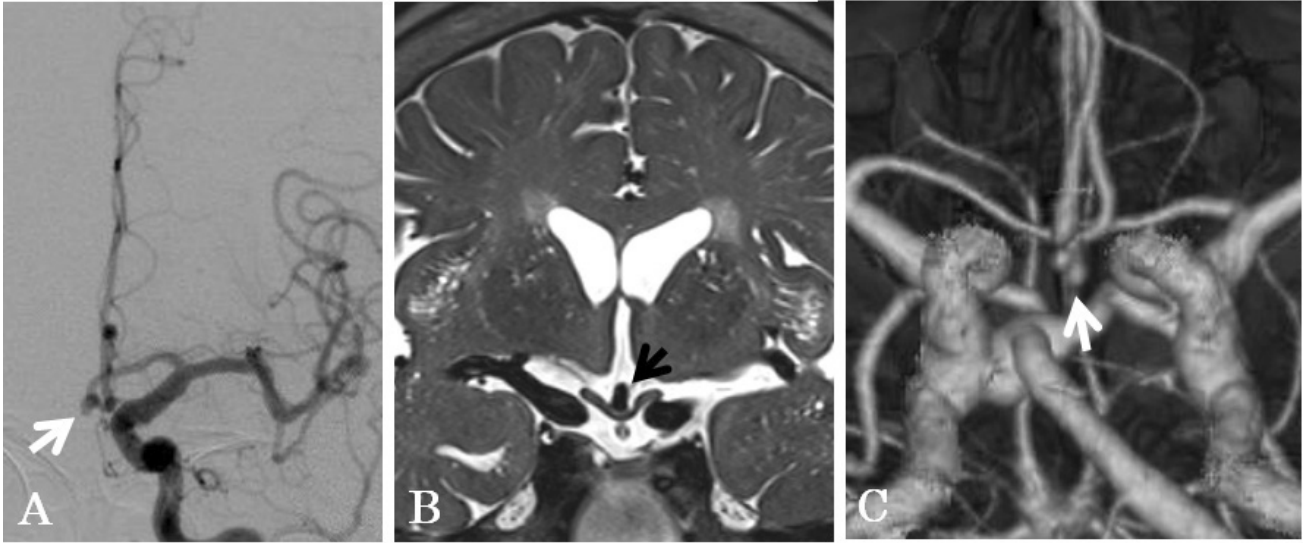


Figure 3



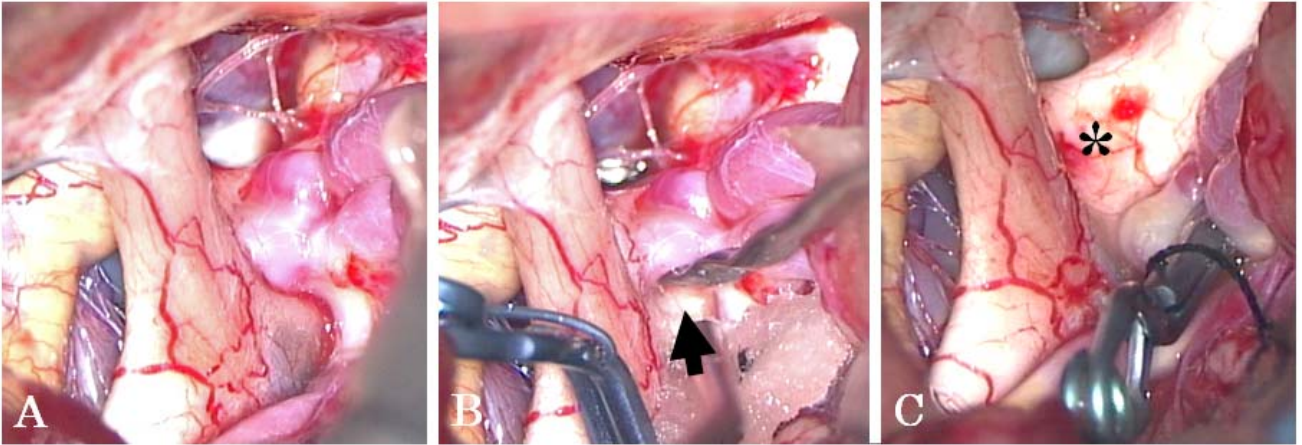


Figure 4