

ORIGINAL ARTICLE

Alternative facial reanimation by masseter muscle transposition combined with tensor fascia lata using the zygomatic arch as a pulley

(brief title):

Facial reanimation by masseter muscle transposition

HIROSHI SHINOHARA<sup>1</sup>, KIYOSHI MATSUO<sup>1</sup>, YOSHIROH OSADA<sup>1</sup>, TATSUYA KAWAMURA<sup>2</sup> & YOHEI TANAKA<sup>1</sup>

*<sup>1</sup>Department of Plastic and Reconstructive Surgery, Shinshu University School of Medicine, Matsumoto, <sup>2</sup>Department of Plastic Surgery, Nagano Red Cross Hospital, Nagano, Japan*

Correspondence: Hiroshi Shinohara, MD, Department of Plastic and Reconstructive Surgery, Shinshu University School of Medicine, 3-1-1 Asahi, Matsumoto, 390-8621, Japan. Tel: 81-263-37-2833. Fax: 81-263-37-1920. E-mail: shinop@hsp.md.shinshu-u.ac.jp

## **Abstract**

We have created an alternative method for facial reanimation. This new surgical procedure involves masseter muscle transposition combined with tensor fascia lata, and the zygomatic arch is used as a trochlea to achieve reconstruction of inferior facial paralysis. This method was used on five patients with facial palsy after excision of a malignant parotid tumour. Wide skin defect exposing the masseter muscle after total parotidectomy was reconstructed with free flap. The concept of this method differs from those underlying other masseter muscle transposition methods for facial reanimation in that force is applied at an upper lateral angle. Our method provided dynamic elevations of the upper lip, the corner of the mouth, and the nasolabial fold for four patients. Thus, we consider our method useful, especially for prompt surgical reconstruction of facial palsy after total parotidectomy with wide cheek skin defect.

**Key Words:** *Facial reanimation, masseter muscle transposition, zygomatic arch, trochlea*

## **Introduction**

Utilization of the temporalis muscle and the masseter muscle innervated by the trigeminal motor nerve is available to restore motion to an extensive area affected by paralysis of the facial nerve. The temporalis muscle is the most suitable for restoring a degree of movement and providing support for the eyelids. In addition, the temporalis muscle is a good substitute motor for lower face reanimation. But there is deformity associated with muscle bulk over the zygomatic arch such as that with temporal muscle transplantation. The masseter muscle is ideally located for reanimating the lower half of the face, and the principle underlying traditional masseter muscle transposition methods is that the muscle will pull the oral commissure and lips laterally and backward when contracted [1-4]. In the muscle bow traction the method using the masseter muscle and a fascial sling, sphincteric control, and buccinator replacement are substituted [5, 6]. Thus, these methods using the masseter muscle are unable to create sufficient elevations of the upper lip and corner of the mouth. Especially, upward movements of the nasolabial fold tend to be insufficient. We have created an alternative surgical procedure using masseter muscle transposition combined with tensor fascia lata using the zygomatic arch as a pulley. Our masseter muscle transfer method, similar to the temporalis muscle transfer method, makes it possible to elevate the nasolabial fold without deformity of muscle bulk. We present the surgical procedure and applications of this method.

## **Patients and methods**

### *Patients*

The method described below was applied to five patients, three men and two women, with facial palsy after total parotidectomy. All the operations were performed primarily. Patient ages ranged from 59-72 (mean 65) years (Table I). The malignant parotid tumour was resected along with cheek skin, and the zygomatic bone and masseter muscle were exposed. The free anterolateral thigh flap was used in four patients, and the free rectus abdominis myocutaneous flap was used in the other patient. Temporal muscle transposition was used for reanimation of the paralysed eye lids in all cases.

### *Surgical procedure*

The masseter muscle might be approached externally through the skin defect when total

parotidectomy was performed. When necessary, preauricular incision with extension to the temporal scalp exposed the masseter muscle and zygomatic arch, and the incision was cosmetically acceptable. The anterior origin of the muscle was usually approached through incision of the nasolabial fold. The anterior tendinous insertion of the masseter muscle was incised preserving the tendinous fibres as they provided a strong attachment for suturing to the tensor fascia lata. Posterior one-third or anterior one-third of the muscle was raised from the zygomatic bone, and incised to obtain mobilisation.

The lateral cheek was undermined and tunnels were made from the zygomatic arch to the nasolabial fold, upper lip, commissure, and lower lip. Careful dissection around the zygomatic arch was performed to allow its use as a trochlea of the tensor fascia lata. A strip of the tensor fascia lata approximately 15 cm in length was then harvested. One end of the sling was sutured to the masseter muscle raised from the zygomatic bone. The other side was passed around the zygomatic arch, pulled through the tunnels and sutured to the nasolabial fold, upper lip, commissure, and lower lip (Figure 1). Overcorrection of the nasolabial fold, corner of the mouth and lip was necessary by applying tension to the sling.

## **Results**

The follow-up period ranged from 10 to 21 months (mean 14.2). We encountered no postoperative complications. During the postoperative follow up four of the five patients obtained dynamic facial reanimation. The range of motion of the oral commissure on the affected side was measured 10 months after surgery. On clenching the jaws, the commissure moved 7 mm in two patients, 4 mm in one patient, and 3 mm in one patient. One patient could not attain movement of the upper lip, the corner of the mouth, and the nasolabial fold (Table I). But, drooping of the commissure and lips, and drooling were not observed in the patient.

### *Case reports*

#### *Case 1*

A 65-year-old man demonstrated a malignant left parotid tumour. The temporal branch of the facial nerve was slightly paralysed on the left side (Figure 2a). Total parotidectomy with radical neck dissection and primary reconstruction for the resultant

facial paralysis was planned. During surgery, the malignant parotid tumour was resected along with cheek skin, and the zygomatic bone and masseter muscle were exposed. One end of the sling of tensor fascia lata was sutured to the masseter muscle (Figure 2b). The other end was passed around the zygomatic arch (Figure 2c), and pulled through the subcutaneous tunnels (Figure 2d). This end was then sutured to the nasolabial fold, upper lip, commissure, and lower lip. Anterolateral thigh free flap was used for reconstruction of the skin defect. The patient was treated with radiation therapy postoperatively. Twenty-one months postoperatively, the patient displayed dynamic movement of the nasolabial fold, upper lip, and lower lip by clenching the teeth to tense the muscle, creating a smile (Figure 2e, f).

### *Case 2*

A 67-year-old man demonstrated recurrence of a malignant left parotid tumour (Figure 3a). Primary reconstruction was performed for facial paralysis resulting from total parotidectomy. The tumour was resected along with cheek skin, extra-auricular canal, and left mandibular condyle (Figure 3b). One end of the sling of tensor fascia lata was sutured to the masseter muscle. The other end was passed around the zygomatic arch, and pulled through the subcutaneous tunnels (Figure 3c). This end was then sutured to the nasolabial fold, upper lip, commissure, and lower lip. The mandibular condyle was reconstructed with a titanium condylar prosthesis, and free rectus abdominis myocutaneous flap was used for reconstruction of the cheek skin and extra-auricular canal (Figure 3d). The patient was treated with radiation therapy postoperatively. Fourteen months postoperatively, the patient displayed dynamic facial reanimation (Figure 3e, f).

### **Discussion**

The temporalis or masseter muscle transpositions require extensive dissections and the patient must relearn how to express the desired emotion [3-4,7]. Despite these demerits, such transpositions provide a good substitute motor for dynamic facial movement. The muscle transpositions shorten the duration of postoperative rehabilitation. The patient is encouraged to begin initial voluntary practice two or three weeks postoperatively, acquiring new and automatic patterns of facial movement [4, 8].

Ipsilateral nerve graft or cross-face nerve grafting offers hope for satisfactory recovery of facial function [9-12]. However, the rate of axonal regrowth is roughly 1 mm/day after the suture line has been crossed [13], and postoperative radiation therapy would damage axonal regrowth. Our patients experienced a quicker return of movement as well as a satisfactory response to postoperative irradiation.

De Castro Correia and Zani [14] noted that the neurovascular bundle of masseter muscle, which arises from the mandibular nerve, and internal maxillary artery passes through the coronoid notch of the mandible, then runs obliquely forward and diagonally downward across the rectangle of the muscle. In order to preserve the nerve supply, separation of the muscle should be carefully performed, especially at the posterior portion of the masseter muscle. Whole-muscle transposition is not necessary in this method, but at least one third will be needed to give the muscle flap sufficient strength [4]. When the anterior one-third of the muscle is used for transposition, the risk of injury of the neuromuscular bundle will be minimised.

Basic muscle movements of the cheeks and lips account for variations in smile characteristics. According to Rubin [15], the human smile can be classified into three categories by the shape of the mouth. The zygomatic major dominant smile is the most commonly seen and produced by lifting the corners of the mouth. The canine smile, the second most common, is a smile in which the upper lip is elevated by contraction of the levator labii superior. Full denture smile is the least common type of smile. If new motor tendons are properly placed into paralysed sites and pulled in an adequate direction, facial movements of the unaffected side may be imitated. The direction and varying strengths of the movements of the new motor tendons affect the smile.

In patients undergoing total parotidectomy resulting in facial paralysis, wide skin defect is presented, and the masseter muscle and zygomatic arch are exposed. Therefore, additional skin incision and dissection of the muscle were minimal in this method. However, the masseter muscle lacks sufficient force and excursion compared with the temporalis muscle [16-17]. The maximum range of motion of the oral commissure on the affected side was 7 mm in our study, which seems to be insufficient to produce a full smile.

For full denture smile, reanimation with pull of the upper lip and the corner of the mouth only is insufficient. In conjunction with our method, using a strip of anterior

masseter muscle transferred from its insertion may control the lower lip and corner of the mouth by a downward pull [18].

Our method provided dynamic facial reanimation for four patients, and static reanimation for one patient. Failure to attain movement in the face may result from the insufficient gliding of the strip of tensor fascia lata over the zygomatic arch.

Additionally, a long fascial strip is used to lengthen the masseter muscle in our method, it may atrophy, slip, or stretch. But recreation of the nasolabial fold and facial symmetry at rest were restored to the patient. Drooling was not observed and the patient was satisfied with the result.

In conclusion, our masseter muscle transfer method is useful, especially for prompt surgical reconstruction of lower facial palsy after total parotidectomy with wide cheek skin defect, especially in older and infirm patients [8].

## References

- [1] Sachs ME, Conley J. Intraoral masseter muscle transposition. *Arch Otolaryngol* 1982; 108: 397-400.
- [2] Sawhney CP. Restoration of function to a lower lip reconstructed by flaps. *Plast Reconstr Surg* 1977; 60: 77-9.
- [3] Sawhney CP. Reanimation of lower lip reconstructed by flaps. *Br J Plast Surg* 1986; 39: 114-7.
- [4] Adams WM. The use of masseter, temporalis and frontalis muscles in the correction of facial paralysis. *Plast Reconstr Surg* 1946; 1: 216-28.
- [5] Maegawa J, Saijo M, Murasawa S. Muscle bow traction method for dynamic facial reanimation. *Ann Plast Reconstr Surg* 1999; 43: 354-8.
- [6] Owens N. Implantation of facial strips through the masseter muscle for surgical correction of facial paralysis. A report of 11 cases. *Plast Reconstr Surg* 1947; 2: 25-36.
- [7] Rangell A. A method for dynamic reconstruction in cases of facial paralysis. *Plast Reconstr Surg* 1958; 21: 214-22.
- [8] Baker DC, Conley J. Regional muscle transposition for rehabilitation of the paralyzed face. *Clin Plast Surg* 1979; 6: 317-31.
- [9] Conley JJ. Facial nerve grafting. *Arch Otolaryngol* 1961; 73: 322-7.
- [10] Fisch U. Facial nerve grafting. *Otolaryngol Clin North Am* 1974; 7: 517-29.
- [11] Anderl H. Cross-face nerve transplant. *Clin Plast Surg*. 1979; 6: 433-49.
- [12] Scaramella LF. On the repair of the injured facial nerve. *Ear Nose Throat J* 1979; 58: 127-33.
- [13] Sunderland S, Cossar DF. The structure of the facial nerve. *Anat Rec* 1953; 116: 147-65.
- [14] De Castro Correia P, Zani R. Masseter muscle rotation in the treatment of inferior facial paralysis. Anatomical and clinical observations. *Plast Reconstr Surg* 1973; 52: 370-3.
- [15] Rubin LR. The anatomy of a smile. Its importance in the treatment of facial paralysis. *Plast Reconstr Surg* 1974; 53: 384-7.
- [16] Zuker RM, Manktelow RT, Hussain G. Facial paralysis. In: Mathes SJ, editor. *Plastic Surgery*. 2nd ed. Philadelphia: Saunders Elsevier; 2006. p 883-916.



- [17] Freeman BS. Review of long-term results in supportive treatment of facial paralysis. *Plast Reconstr Surg* 1979; 63: 214-8.
- [18] Ueda K, Harii K, Yamada A. Free vascularized double muscle transplantation for the treatment of facial paralysis. *Plast Reconstr Surg* 1995; 95: 1288-98.

## Figure Legends

Figure 1. Schematic representation of the implanted fascial loop. The zygomatic arch is used as a trochlea.

Figure 2. Case 1. (a) Preoperative photograph showing paralysis of the left temporal branch. (b) Intraoperative view. The masseter muscle is elevated and the strip of tensor fascia lata is sutured to it. (c) The fascial strip is passed around the zygomatic arch. (d) Transposition to the upper lip, nasolabial fold, lower lip, and commissure. (e, f) Postoperative view. The patient is smiling by clenching the teeth.

Figure 3. Case 2. (a) Preoperative condition. (b) Intraoperative view. Total parotidectomy and neck dissection were performed. (c) The fascial strip is passed around the zygomatic arch. (d) An intracanalicular stent is inserted as a retainer in the extra-auricular canal. (e, f) Postoperative view. Clenching of the teeth produced movement of the upper lip, nasolabial fold, lower lip, and commissure.

Table I. Details of patients.

Case No.	Sex	Age (years)	Range of motion of commissure (mm)
1	Female	72	4
2	Male	65	7
3	Male	67	7
4	Male	59	3
5	Female	61	0

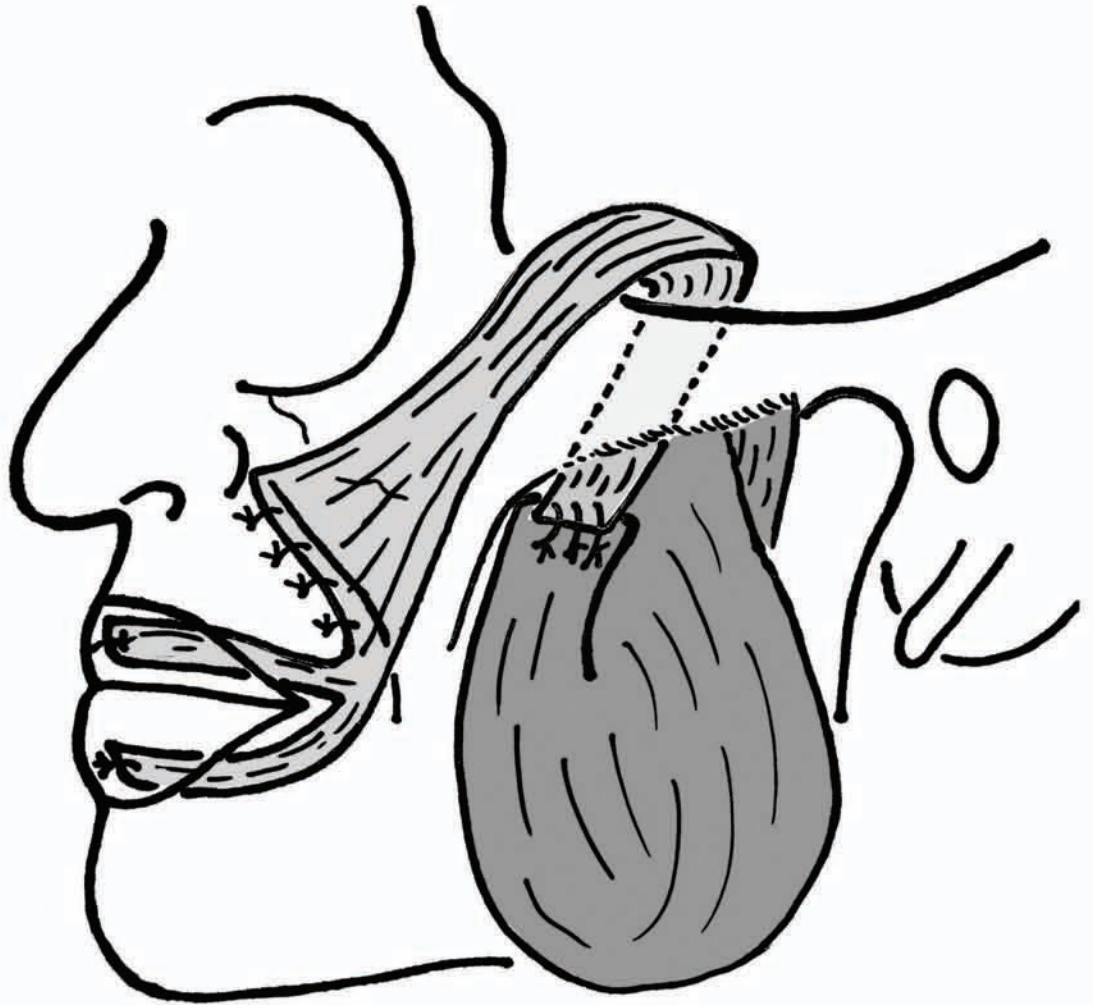


Figure 1

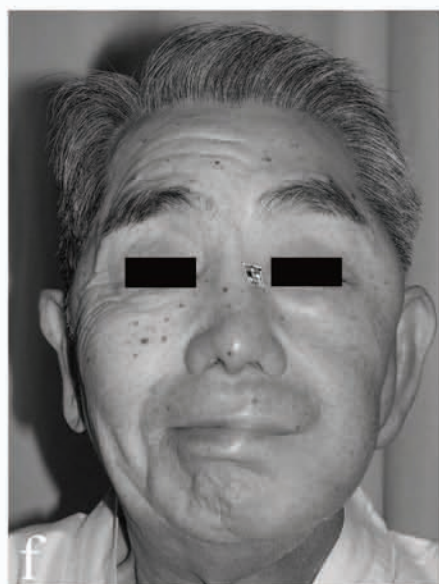
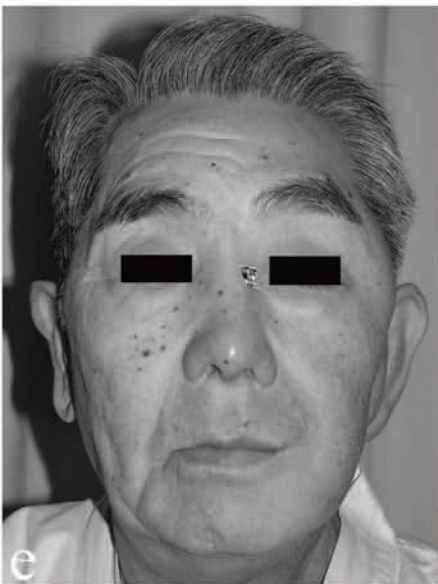
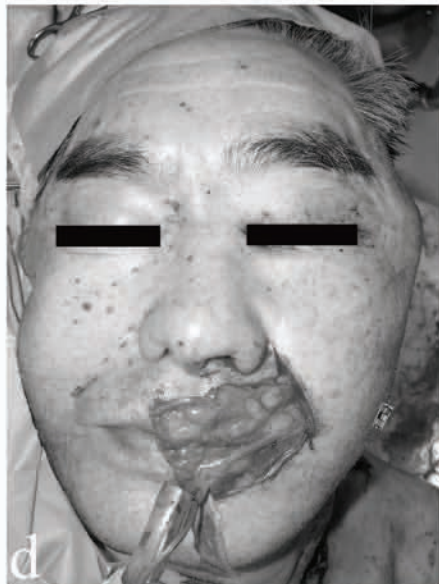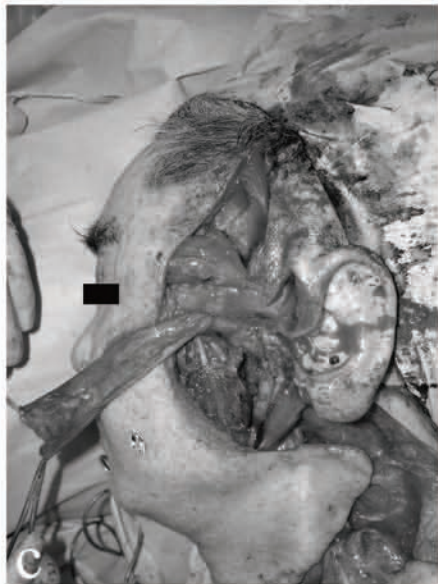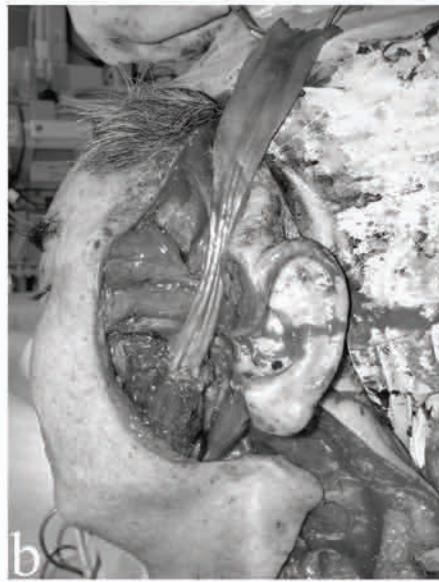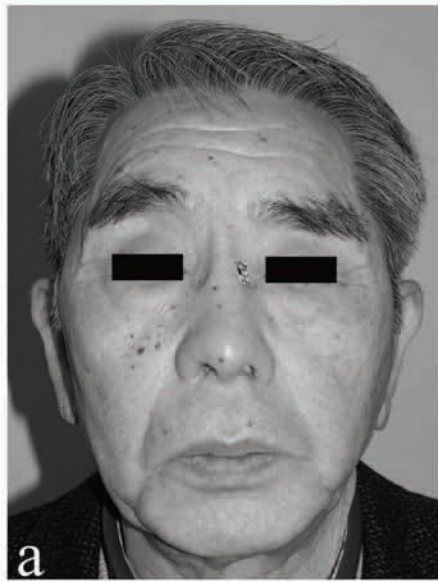Figure 2



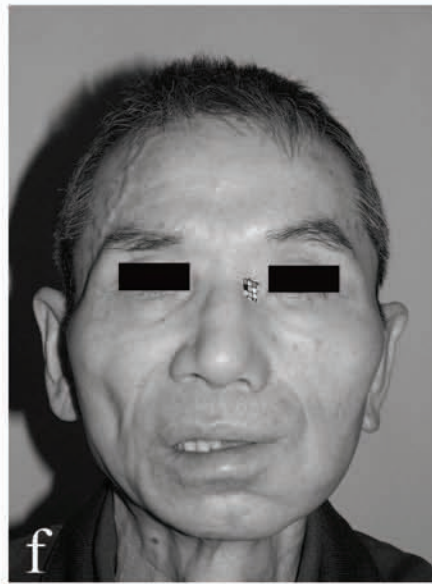
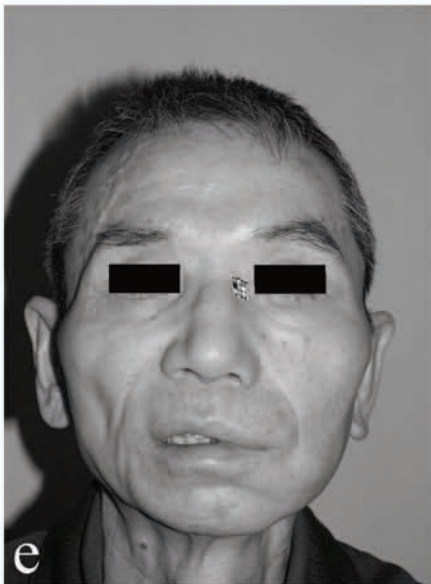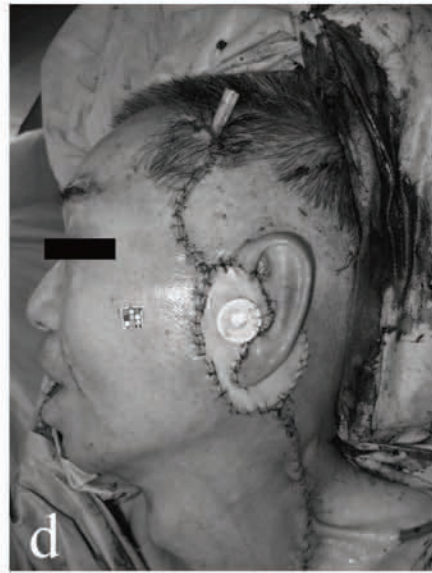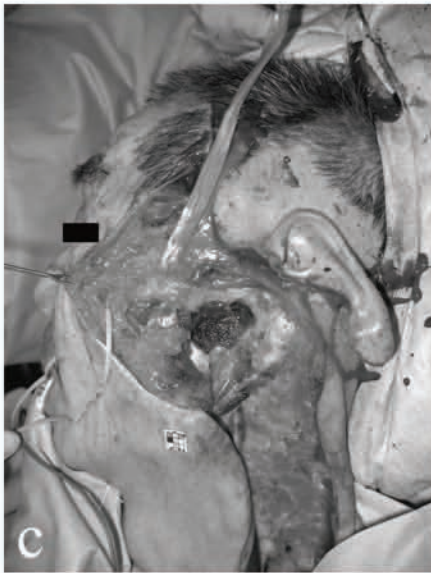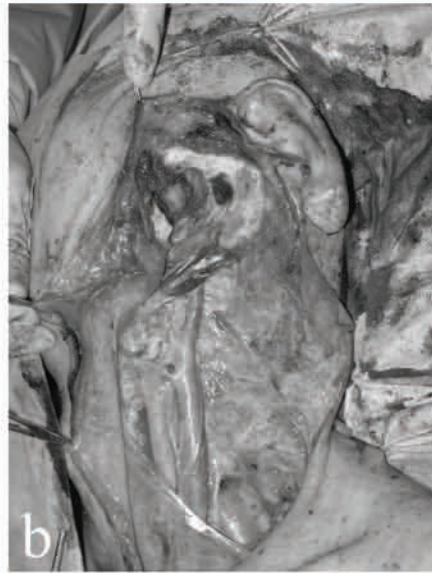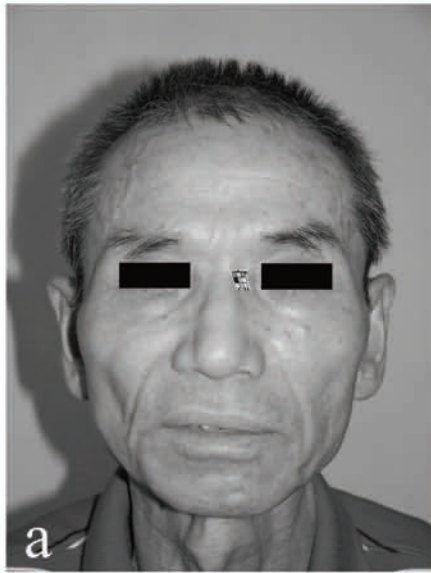


Figure 3