

Emergency Operation for Non-Hodgkin Lymphoma of the Small Intestine

Naohiko KOIDE^{1)*}, Yasushi SEKINO¹⁾, Akira SUZUKI¹⁾
 Taiji AKAMATSU²⁾ and Shinichi MIYAGAWA¹⁾

1) *Department of Surgery, Shinshu University School of Medicine*

2) *Department of Gastroenterology, Shinshu University School of Medicine*

We report 5 cases of non-Hodgkin lymphoma of the small intestine (S-NHL) treated with emergency operation. These cases showed three reasons for emergency operation: [1] massive hemorrhage with shock before diagnosis of S-NHL (Case 1), [2] obstruction of the small intestine before and during chemotherapeutic treatment for S-NHL (Cases 2 and 3), and [3] spontaneous perforation with peritonitis before diagnosis of S-NHL or iatrogenic perforation following chemotherapy (Cases 4 and 5). For tumor discovery, double-balloon endoscopy of the small intestine was employed in 3 cases. Three tumors were histologically diagnosed before treatment, while 2 were histopathologically diagnosed using the resected specimens after emergency operation. An advanced stage of NHL was frequently observed. No surgical mortality occurred. We always consider the possibility of emergency operation before, during, and after the diagnosis and treatment of patients with S-NHL. *Shinshu Med J 60 : 21–25, 2012*

(Received for publication August 10, 2011 ; accepted in revised form October 7, 2011)

Key words : lymphoma, small intestine, emergency, surgery

I Introduction

Non-Hodgkin lymphoma (NHL) is the third most common malignant neoplasm of the small intestine¹⁾. The small intestine is the second most common site for NHL of the gastrointestinal (GI) tract²⁾, and NHL of the small intestine (S-NHL) is observed in approximately 20 % of GI-NHL in Japan³⁾. Previously, surgery was frequently adopted for GI-NHL patients for both the treatment and histologic diagnosis⁴⁾. However, initial chemotherapy has recently been performed in GI-NHL patients³⁾⁵⁾. Recently, new endoscopic techniques, including capsule-endoscopy and DBE, have been made available for several tumors and disorders of the small intestine⁶⁾⁷⁾. These devices have contributed to the diagnosis of S-NHL, including not only the detection of S-NHL but also the sampling of biopsy speci-

mens⁸⁾⁹⁾. The role of surgery in S-NHL could change after the development of these endoscopic techniques and devices. However, surgery, especially emergency operations due to acute abdominal conditions, should still be considered for S-NHL patients as perforation or obstruction of the small intestine has been reported in S-NHL patients with or without chemotherapy¹⁰⁾. We report 5 cases of S-NHL that required emergency operation.

II Case Reports

Case 1, a 75-year-old woman, was operated on for massive hemorrhage of the GI tract, clinically showing dynamic shock. Before surgery, no cause of massive intestinal hemorrhage had been identified. At laparotomy, a jejunal tumor was detected and removed. The resected tumor was histopathologically diagnosed as diffuse large B-cell lymphoma (DLBCL) of the jejunum after surgery. Three months after the operation, the patient died of the systemic involvement of NHL, although the postoperative course was uneventful.

* Corresponding author : Naohiko Koide
 Department of Surgery, Shinshu University School of Medicine, 3-1-1 Asahi, Matsumoto, Nagano 390-8621 Japan

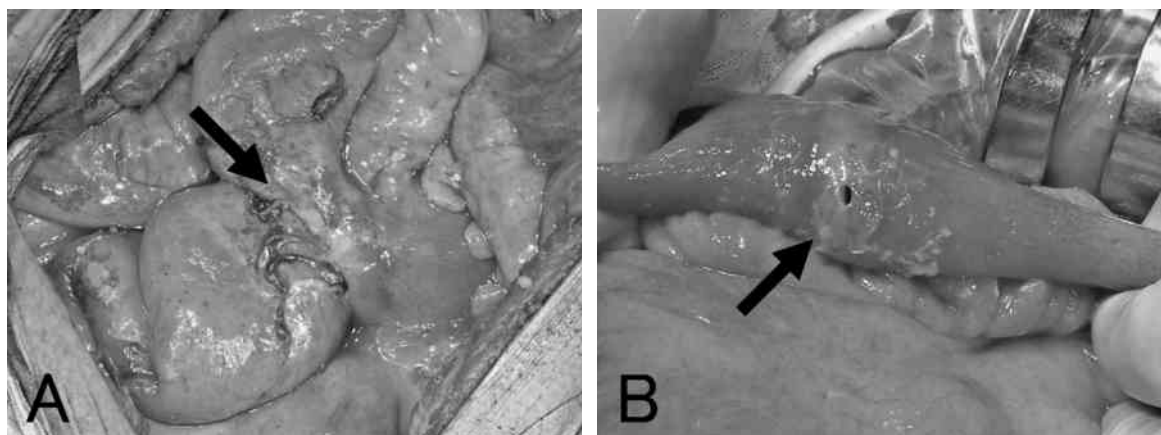


Fig. 1 Operative findings

- A Case 3 : Intestinal obstruction caused by repeated chemotherapy. The arrow shows that the obstruction originated from the intestinal lymphoma with degenerative and fibrous changes.
- B Case 4 : Spontaneous perforation of the intestinal lymphoma. The arrow shows the perforation.

Case 2, a 68-year-old man, underwent an emergency operation involving partial resection of the ileum. Intestinal obstruction due to rapid enlargement of the ileal tumor was observed when the patient was admitted for chemotherapy for DLBCL of the ileum detected by double balloon endoscopy (DBE). The postoperative course was uneventful. After surgery, chemotherapy using cyclophosphamide, doxorubicin hydrochloride, vincristine, and methylprednisolone with rituximab (R-CHOP) was performed. The patient is well without any recurrence 42 months after surgery.

Case 3, a 52-year-old man, showed intestinal obstruction after 4 cycles of CHOP chemotherapy for T-cell lymphoma of the jejunum diagnosed by DBE. Although conservative treatment for the intestinal obstruction using a long intestinal tube was performed, it did not improve. The patient underwent an emergency operation (Fig. 1A). The postoperative course was uneventful. Although further chemotherapy was performed, the patient died of central nervous system involvement of S-NHL 18 months after surgery.

Case 4, a 78-year-old man, was operated on due to diffuse peritonitis with sudden onset. At laparotomy, a perforated tumor was detected in the jejunum and removed (Fig. 1B). The resected tumor was histopathologically diagnosed as DLBCL after surgery. The postoperative course was uneventful,

and the patient received systemic chemotherapy using R-CHOP. The patient is well without any recurrence 36 months after surgery.

Case 5, a 78-year-old woman, had diffuse peritonitis due to a perforation of the duodenum, when balloon dilation was endoscopically performed for stenosis caused by repeated chemotherapy using CHOP for duodenal DLBCL. The patient surgically underwent wide drainage of the abdominal cavity. Although infection of the postoperative surgical site was observed, the patient survived for 61 months after surgery without recurrence. The clinicopathologic features of the 5 S-NHL cases treated by emergency operation are summarized in Table 1. All patients satisfied the diagnostic criteria for primary lymphoma of the gastrointestinal tract described by Lewin et al¹¹⁾. The histologic classification of NHL was carried out according to WHO criteria¹²⁾. The NHL stage was determined according to the Lugano International Conference Classification¹³⁾.

III Discussion

Emergency surgery has occasionally been necessary for S-NHL patients. There are a few recent reports concerning limited investigation of this specific situation regarding S-NHL¹⁴⁾¹⁵⁾, although several reports concerning emergency surgery for small intestinal tumors, including gastrointestinal

Table 1 Cases of small intestinal non-Hodgkin lymphoma treated by emergency operation

Cases	Age/Sex	Symptom	Detection	Reason for surgery	Clinicopathologic features			Before surgery		After Surgery		Surgical morbidity	Outcome after surgery (months)
					Site	Size (mm)	Histology	Stage*	Cx	Rx	Cx		
1	75/F	bleeding	surgery	shock	jejunum	54	DLBCL	IV	-	-	-	SSI	died (3)
2	68/M	pain	DBE	ileus	ileum	60	DLBCL	IV	-	-	+	-	alive (42)
3	52/M	pain	DBE	ileus	jejunum	150	T-cell	II _E	+	-	+	-	died (18)
4	78/M	pain	surgery	perforation	jejunum	40	DLBCL	II _E	-	-	+	-	alive (36)
5	78/F	pain	DBE	perforation	duodenum	48	DLBCL	II ₁	+	-	+	-	alive (61)

*, Lugano staging classification ; Cx, chemotherapy ; Rx, radiotherapy.

DBE, double balloon endoscopy ; DLBCL, diffuse large B-cell lymphoma ; SSI, surgical site infection.

stromal tumor and other tumors, are available¹⁶⁾¹⁷⁾. The patients were urgently operated on for various reasons such as massive bleeding and dynamic shock (Case 1), obstruction of the small intestine without and with chemotherapy (Cases 2 and 3), and spontaneous or iatrogenic perforation of the small intestine (Cases 4 and 5). These emergency situations were encountered in every period around the treatment of S-NHL. We should always consider the possibility of emergency surgery before, during, and after treatment in patients with S-NHL.

Intestinal hemorrhage has been clinically observed in approximately 10 % of S-NHL : 6.3 % reported by Koch et al²⁾ and 14.3 % by Daum et al¹⁸⁾. Massive hemorrhage caused by S-NHL has rarely been observed in patients involving the lower GI distal to the ligament of Treitz, and its frequency was approximately 1-2 % of patients with small intestinal bleeding¹⁹⁾²⁰⁾. Massive hemorrhage of S-NHL is a fatal complication, although Case 1 with dynamic shock was cured by emergency surgery and intensive care. The patient did not receive chemotherapy after surgery, because the general condition worsened. It was expected that the clinical outcome would be poor. The emergent state of S-NHL patients is an issue concerning the clinical outcome after surgery.

Regarding intestinal obstruction, NHL was the second-most common tumor of the small intestine¹⁷⁾, and it was frequently observed in S-NHL patients²⁾²¹⁾. This complication can affect the diagnosis and treatment of S-NHL. Usually, elective surgery was performed for intestinal stenosis caused by S-NHL before chemotherapy, and chemotherapy was subsequently performed. Emergency surgery would be required for S-NHL patients with intestinal obstruction, and two modes of obstruction should be considered for S-NHL patients: chemotherapeutic complications of S-NHL, such as Case 3; and optimal surgery for an unknown tumor with obstruction of the small intestine.

Perforation of the small intestine has sometimes been observed in patients with S-NHL. Koch et al²⁾

reported that it was observed in 9.4 % of S-NHL patients. Daum et al¹⁸⁾ reported that it was observed in 25 % of S-NHL patients, and there was a high rate (37 %) in T-cell lymphoma. Free perforation of the small intestine or tumors occurs spontaneously or after chemotherapy in patients with S-NHL¹⁴⁾²²⁾. When NHL is treated by effective chemotherapy, perforation of the GI tract may be a potential complication caused by tumor degeneration. However, as in Case 5, iatrogenic perforation due to balloon dilation for stenosis after chemotherapy for S-NHL has been rarely reported. New technical devices for endoscopy have been developed and archived for small intestinal disorders including S-NHL. We considered these complicated perforations even though they are unlikely in S-NHL patients, involving not only chemotherapeutic effects but also iatrogenic complications.

Surgery for malignant tumors of the small intestine, including S-NHL, has often been associated with a high mortality rate; previous reports demonstrated a rate of 5 % or more¹⁵⁾¹⁷⁾²³⁾. In our series, no surgical mortality was observed. Furthermore, intestinal perforation has been associated with a poor prognosis in patients with S-NHL¹⁵⁾¹⁸⁾. Two of the 5 patients showed a poor outcome, with lower-level morbidity and morbidity after emergency

operation. As a reason for this, emergent situations such as perforation and obstruction of the small intestine are often characterized by systemic inflammatory response syndrome, and an immunosuppressed state may be observed. However, in S-NHL patients, no information has been made available regarding these emergent situations, and further studies may be needed. Careful management of S-NHL patients undergoing emergency surgery is required for a safe postoperative course, and promoting effective postoperative treatment and prolonged survival.

In conclusion, the recent role of surgery for S-NHL patients has changed after the clinical presentation of new endoscopic techniques and devices, such as DBE and capsule-endoscopy, for the small intestine. We should consider the possibility of emergency surgery before, during, and after management and treatment in patients with S-NHL.

Acknowledgement

We gratefully acknowledge Dr. Kumiko Shirohata (Department of Internal Medicine, Iida Municipal Hospital), and Dr. Masato Kitazawa, Dr. Risako Hiraga and Dr. Satoshi Ishizone (Department of Surgery, Shinshu University School of Medicine) for their considerable contributions to this paper.

References

- 1) Weiss NS, Yang CP : Incidence of histologic types of cancer of the small intestine. *Natl Cancer Inst* 78 : 653-665, 1987
- 2) Koch P, del Valle F, Berdel WE, Willich NA, Reers B, Hiddemann W, Grothaus-Pinke B, Reinartz G, Brockmann J, Temmesfeld A, Schmitz R, Rube C, Probst A, Jaenke G, Bodenstern H, Junker A, Pott C, Schultze J, Heinecke A, Parwaresch R, Tiemann M; German Multicenter Study Group : Primary gastrointestinal non-Hodgkin's lymphoma : I. Anatomic and histologic distribution, clinical features, and survival data of 371 patients registered in the German Multicancer Study GIT NHL 01/92. *J Clin Oncol* 19 : 3861-3873, 2001
- 3) Nakamura S, Matsumoto T, Iida M, Yao T, Tsuneyoshi M : Primary gastrointestinal lymphoma in Japan. A clinicopathologic analysis of 455 patients with special reference to its time trends. *Cancer* 97 : 2462-2473, 2003
- 4) Rackner VL, Thirlby RC, Ryan JA : Role of surgery in multimodality therapy for gastrointestinal lymphoma. *Am J Surg* 161 : 570-575, 1991
- 5) Koch P, del Valle F, Berdel WE, Willich NA, Reers B, Hiddemann W, Grothaus-Pinke B, Reinartz G, Brockmann J, Temmesfeld A, Schmitz R, Rube C, Probst A, Jaenke G, Bodenstern H, Junker A, Pott C, Schultze J, Heinecke A, Parwaresch R, Tiemann M; German Multicenter Study Group : Primary gastrointestinal non-Hodgkin's lymphoma : II. Combined surgical and conservative or conservative management only in localized gastric

- lymphoma - results of the prospective German Multicancer Study GIT NHL 01/92. *J Clin Oncol* 19 : 3874-3883, 2001
- 6) Yamamoto H, Sekine Y, Sato Y, Higashizawa T, Miyata T, Iino S, Ido K, Sugano K : Total endoscopy with a nonsurgical steerable double-balloon method. *Gastrointest Endosc* 53 : 216-220, 2001
 - 7) Bailey AA, Debinski HS, Appleyard MN, Remedios ML, Hooper JE, Walsh AJ, Selby WS : Diagnosis and outcome of small bowel tumors found by capsule endoscopy : a three-center Australian experience. *Am J Gastroenterol* 101 : 2237-2243, 2006
 - 8) Flieger D, Keller R, May A, Ell C, Fischbach W : Capsule endoscopy in gastrointestinal lymphomas. *Endoscopy* 37 : 1174-1180, 2005
 - 9) Manabe N, Tanaka S, Fukumoto A, Nakao M, Kamino D, Chayama K : Double-balloon endoscopy in patients with GI bleeding of obscure origin. *Gastrointest Endosc* 64 : 135-140, 2006
 - 10) d'Amore F, Brincker H, Grønbaek K, Thorling K, Pedersen M, Jensen MK, Andersen E, Pedersen NT, Mortensen LS : Non-Hodgkin's lymphoma of the gastrointestinal tract : a population based analysis of incidence, geographic distribution, clinicopathological presentation features, and prognosis. Danish Lymphoma Study Group. *J Clin Oncol* 12 : 1673-1684, 1994
 - 11) Lewin KJ, Ranchod M, Dorfman RF : Lymphomas of the gastrointestinal tract : a study of 117 cases presenting with gastrointestinal disease. *Cancer* 42 : 693-707, 1978
 - 12) Jaffe ES, Harris NL, Stein H, Vardiman JW, ed. World Health Organization classification of tumours. Pathology and genetics of tumours of hematopoietic and lymphoid tissues. Lion : IARC Press, 2001
 - 13) Rohantiner A, d'Amore F, Coiffier B, Crowther D, Gospodarowicz M, Isaacson P, Lister TA, Norton A, Salem P, Shipp M, Somers R. Report on a workshop convened to discuss the pathological and staging classifications of gastrointestinal tract lymphoma. *Ann Oncol* 5 : 397-400, 1994
 - 14) Samel S, Wagner J, Hofheinz R, Sturm J, Post S : Malignant intestinal non-Hodgkin's lymphoma from the surgical point of view. *Onkologie* 25 : 268-271, 2002
 - 15) Ara C, Coban S, Kayaalp C, Yilmaz S, Kirimlioglu V : Spontaneous intestinal perforation due to non-Hodgkin's lymphoma : evaluation of eight cases. *Dig Dis Sci* 52 : 1752-1756, 2007
 - 16) Catena F, Ansaloni L, Gazzotti F, Gagliardi S, Di Saverio S, De Cataldis A, Taffurelli M : Small bowel tumours in emergency surgery : specificity of clinical presentation. *ANZ J Surg* 75 : 997-999, 2005
 - 17) Beltran MA, Cruces KS : Primary tumors of jejunum and ileum as a cause of intestinal obstruction : a case control study. *Int J Surg* 5 : 183-191, 2007
 - 18) Daum S, Ullrich R, Heise W, Dederke B, Foss HD, Stein H, Thiel E, Zeitz M, Riecken EO : Intestinal non-Hodgkin's lymphoma : a multicenter prospective clinical study from the German study group on intestinal non-Hodgkin's lymphoma. *J Clin Oncol* 21 : 2740-2746, 2003
 - 19) Anand AC, Patnaik PK, Bhalla VP, Chaudhary R, Saha A, Rana VS : Massive lower intestinal bleeding - a decade of experience. *Trop Gastroenterol* 22 : 131-134, 2001
 - 20) Al Qahtani AR, Satin R, Stern J, Gordon PH : Investigative modalities for massive lower gastrointestinal bleeding. *World J Surg* 26 : 620-625, 2002
 - 21) Yin L, Chen CQ, Peng CH, Chen GM, Zhou HJ, Han BS, Li HW : Primary small-bowel non-Hodgkin's lymphoma : a study of clinical features, pathology, management and prognosis. *J Int Med Res* 35 : 406-415, 2007
 - 22) Sakakura C, Hagiwara A, Nakanishi M, Yasuoka R, Shirasu M, Togawa T, Taniwaki M, Yamagishi H : Bowel perforation during chemotherapy for non-Hodgkin's lymphoma. *Hepatogastroenterology* 46 : 3175-3177, 1999
 - 23) Krouse RS : Surgical management of malignant bowel obstruction. *Surg Oncol Clin N Am* 13 : 479-490, 2004
- (2011. 8. 10 received ; 2011. 10. 7 accepted)