

Spontaneous Resolution of Left Ventricular Outflow Tract Obstruction in the Course of Newly-Developed Mitral Valve Prolapse in a Hypertrophic Cardiomyopathy Patient

Takahisa MARUYAMA*, Takahiro SAKAI and Toshio KASAI

Division of Cardiology, Nagano Municipal Hospital

A 63-year-old man was diagnosed with hypertrophic obstructive cardiomyopathy. Echocardiography revealed asymmetrical left ventricular hypertrophy, systolic anterior movement (SAM) of mitral leaflets causing an outflow tract pressure gradient of 52 mmHg, and moderate mitral regurgitation (MR) directed posteriorly in the left atrium. Four years later, when the patient was admitted for mild congestive heart failure, SAM and left ventricular outflow obstruction were absent, and prolapse of the posterior mitral leaflet was causing anteriorly-directed severe MR. Rupture of the chordae tendineae was responsible for the mitral prolapse and for the abolition of the outflow obstruction. *Shinshu Med J 59 : 259–263, 2011*

(Received for publication March 9, 2011 ; accepted in revised form April 6, 2011)

Key words : systolic anterior movement, hypertrophic cardiomyopathy, mitral valve prolapse

I Introduction

Among the various features of hypertrophic cardiomyopathy (HCM), left ventricular outflow obstruction with systolic anterior movement (SAM) of the mitral leaflets significantly influences the clinical outcome. Although infrequent, rupture of the chordae tendineae is reported to complicate obstructive HCM. We report a case of HCM with spontaneous disappearance of SAM, presumably caused by mitral valve prolapse with ruptured chordae tendineae.

II Case Report

Our patient first came to our hospital at the age of 63, seeking a consultation because of mild dyspnea on exertion. The pulse rate was 66 beats/min and regular ; blood pressure was 104/80 mmHg. There were no rales. A systolic ejection murmur of grade 3/6 was heard. The extremities were not

edematous. Electrocardiography showed a normal sinus rhythm and a complete right bundle branch block. On chest X-ray study, pulmonary congestion was not seen, and the cardiothoracic ratio was 51 %. Echocardiography revealed that the size and contraction of the left ventricle were normal (end-diastolic dimension, 36 mm ; ejection fraction, 73 %), but that asymmetrical hypertrophy (inter-ventricular septal thickness, 17 mm) and SAM were causing obstruction of the left ventricular outflow tract with a peak flow velocity of 3.6 m/sec on continuous wave Doppler (i.e. calculated pressure gradient, 52 mmHg). Moderate mitral regurgitation (MR) was observed with the jet directed posteriorly in the dilated left atrium (dimension, 54 mm) (Fig. 1, Table 1). A left-sided cardiac catheterization study revealed that the coronary arteries were normal and that the intra-ventricular pressure gradient was about 30 to 40 mmHg. The patient was accordingly diagnosed with hypertrophic obstructive cardiomyopathy.

Several months later, he experienced a single episode of paroxysmal atrial fibrillation accompanied by a considerable decrease in blood

* Corresponding author : Takahisa Maruyama
Division of Cardiology, Nagano Municipal Hospital,
1333-1 Tomitake, Nagano-city, Nagano-prefecture
381-8551, Japan

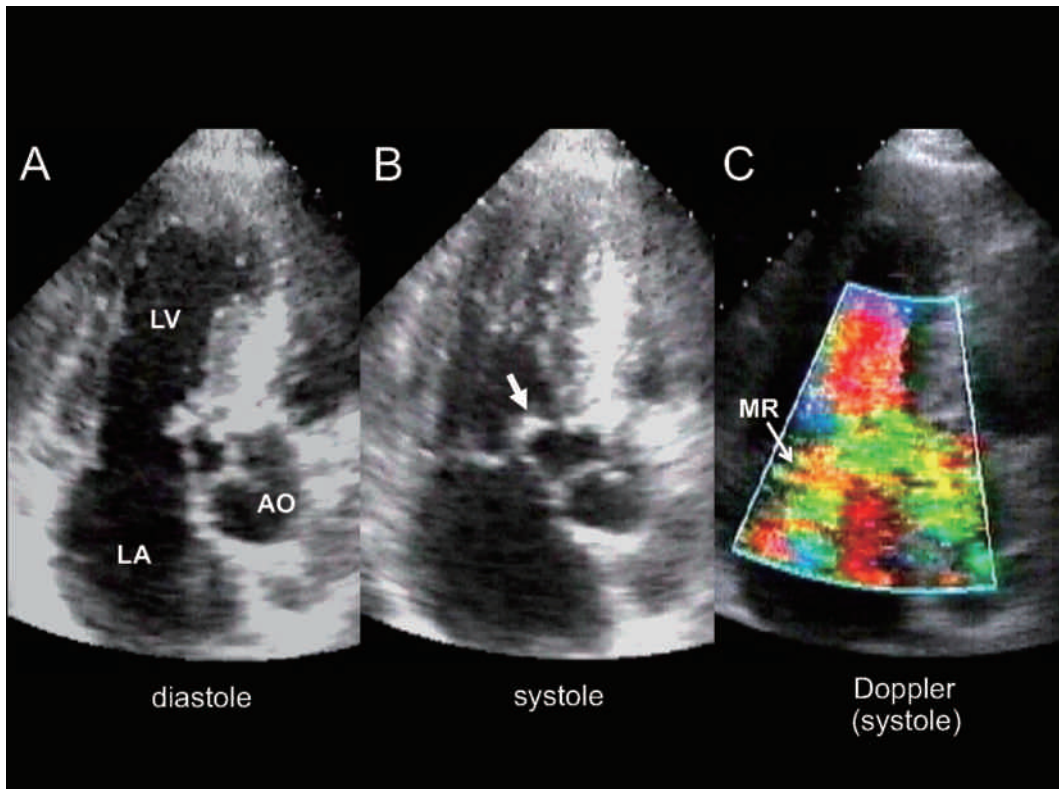


Fig. 1 Echocardiographic images in transthoracic apical long axis view at the first presentation. A, Two-dimensional image on diastole. Asymmetrical left ventricular hypertrophy was seen. B, Two-dimensional image on systole. Systolic anterior movement of the anterior mitral leaflet (arrow) caused outflow obstruction. C, Color Doppler flow image on systole. Mitral regurgitation jet was oriented posteriorly in the left atrium. AO=aorta; LA=left atrium; LV=left ventricle; MR=mitral regurgitation.

Table 1 Echocardiographic findings

	At the first presentation	Four years later
LVDd (mm)	36	40
LVDs (mm)	16	18
IVST (mm)	17	17
EF (%)	73	70
LAD (mm)	52	55
LVOT obstruction	(+)	(-)
SAM	(+)	(-)
PML prolapse	(-)	(+)
MR grade	moderate	severe
MR direction	poteriorly	anteriorly

EF=ejection fraction of left ventricle; IVST=inter-ventricular septal thickness; LAD=left atrial dimension; LVDd=left ventricular diastolic dimension; LVDs=left ventricular systolic dimension; LVOT=left ventricular outflow tract; MR=mitral regurgitation; PML=posterior mitral leaflet; SAM=systolic anterior movement of mitral leaflet

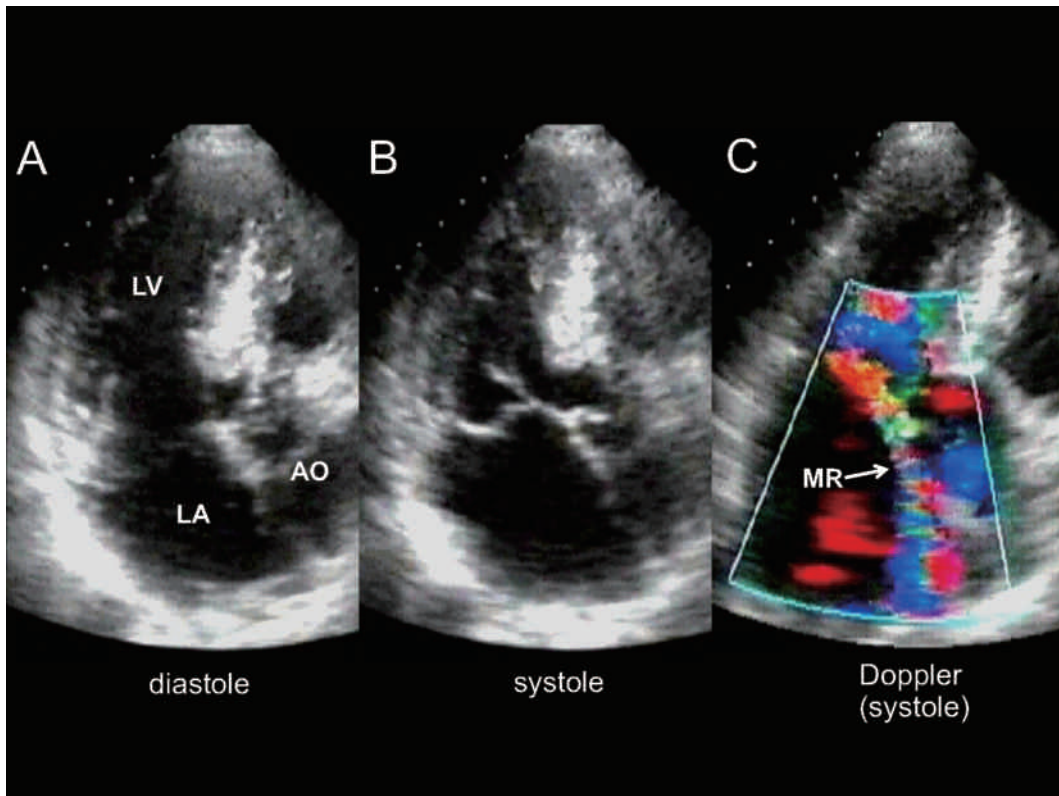


Fig. 2 Echocardiographic images in transthoracic apical long axis view four years after the first presentation. A, Two-dimensional image on diastole. B, Two-dimensional image on systole. There was no systolic anterior movement of the anterior mitral leaflet, and the outflow tract was not obstructive. The posterior mitral leaflet bulged into the left atrium. C, Color Doppler flow image on systole. The jet of severe mitral regurgitation was oriented anteriorly. AO=aorta; LA=left atrium; LV=left ventricle; MR=mitral regurgitation.

pressure by 20 to 30 mmHg. Disopyramide and atenolol were prescribed, and he subsequently remained in NYHA class I to II with no further events.

At age 67, however, four years after the first presentation, overexertion brought on an episode of nocturnal dyspnea, and the patient was admitted under a diagnosis of congestive heart failure. Pulmonary congestion improved promptly in response to vasodilators and diuretics. Although change in left ventricle size had been mild since the first presentation, as seen in an echocardiogram, SAM and outflow obstruction had disappeared; instead, severe MR was noted, in the form of a jet along the anterior wall of the left atrium, caused by the prolapse of the central and medial portions of the posterior leaflet (Fig. 2, Table 1). Transesophageal echocardiography confirmed that rupture of the

chordae tendineae was responsible for the prolapse of the posterior mitral leaflet (Fig. 3).

The patient chose to continue with medical therapy for the following two years, until he experienced another episode of congestive heart failure. Then, his mitral valve was repaired surgically. Replacement by the mechanical prosthetic valve abolished the mitral regurgitation, and the left ventricular outflow obstruction no longer occurred.

III Discussion

HCM patients exhibit structural diversity of the mitral valve apparatus; some formations can cause SAM and left ventricular outflow obstruction¹²⁾. SAM often accompanies MR without prolapse of leaflets; in such cases the degree of MR depends on the coaptation of leaflets, especially on the ability of the posterior leaflet to follow the anterior leaflet³⁾,

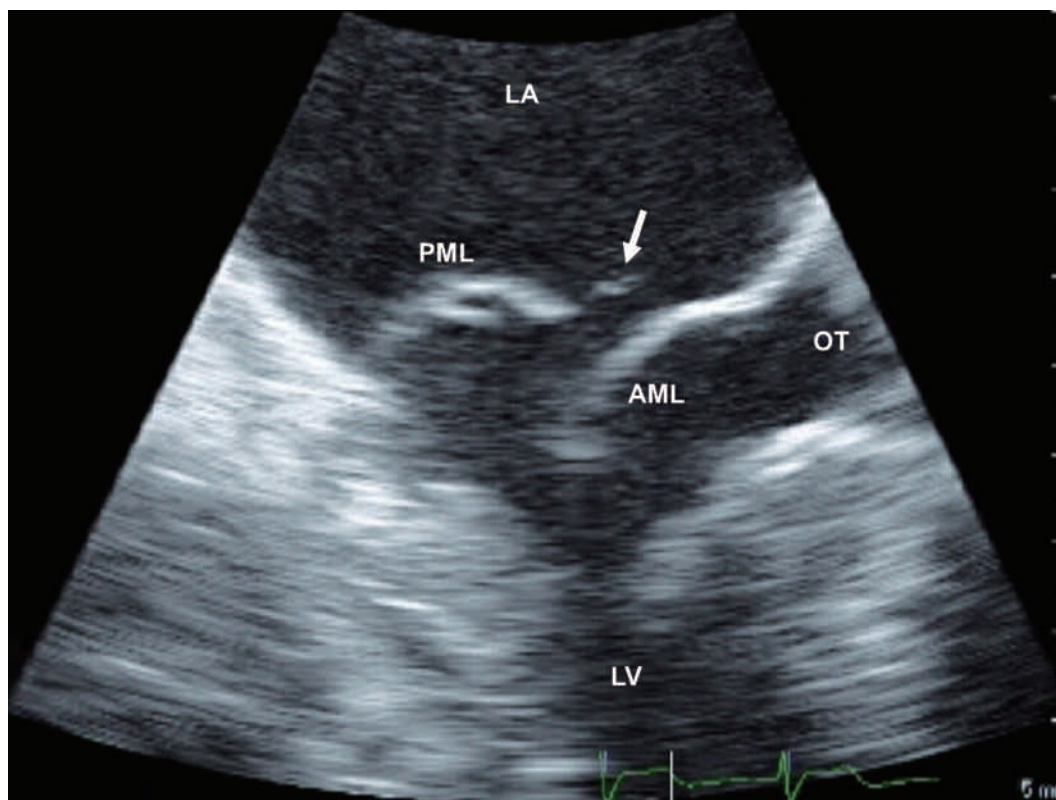


Fig. 3 Transesophageal echocardiogram on systole four years after the first presentation. A torn chorda (arrow) is attached to the tip of the prolapsed posterior mitral leaflet. AML=anterior mitral leaflet; LA=left atrium; LV=left ventricle; OT=outflow tract of left ventricle; PML=posterior mitral leaflet.

and the regurgitation jet is oriented posteriorly in the left atrium⁴). Thus, at our patient's first presentation, his MR had been considered to be secondary to SAM and outflow obstruction.

Four years later, however, our patient's SAM had disappeared and the severity and direction of his MR had markedly changed. His MR, clearly independent of SAM, was caused by prolapse of the posterior leaflet due to rupture of the chordae tendineae.

Petrone et al. reported that mitral valve prolapse was identified in only 3% of consecutive HCM patients⁵); however, there are several reports describing obstructive HCM cases complicated with rupture of the chordae tendineae⁶⁻¹⁰). Although it is controversial whether rupture of the chordae tendineae may be secondary to HCM or may be a separate primary entity, one speculation is that long-term mechanical stress might result in degeneration of the chordae tendineae in obstructive HCM

patients.

In most of the reported cases, left ventricular outflow obstruction persisted at the occurrence of rupture of the chordae tendineae^{6-8,10}). On the other hand, our case and that reported by Araujo et al.⁹) are unique as the pressure gradient and SAM disappeared after rupture of the chordae tendineae. In these patients, the rupture of the chordae tendineae may have influenced the behavior of mitral structures leading the disappearance of SAM, and a subtle dilatation of outflow tract through volume overload might have diminished the flow velocity, thereby abolishing the suction effect.

In treating HCM patients with SAM, the origin and influences of accompanying MR should be determined, and the possibility of spontaneous improvement in the extent of outflow obstruction should be kept in mind.

References

- 1) Kleus HG, Maron BJ, Dollar AL, Roberts WC : Diversity of structural mitral valve alterations in hypertrophic cardiomyopathy. *Circulation* 85 : 1651-1660, 1992
- 2) Klues HG, Roberts WC, Maron BJ : Morphological determinants of echocardiographic patterns of mitral valve systolic anterior motion in obstructive hypertrophic cardiomyopathy. *Circulation* 87 : 1570-1579, 1993
- 3) Schwammenthal E, Nakatani S, He S, Hopmeyer J, Sagie A, Weyman AE, Lever HM, Yoganathan AP, Thomas JD, Levine RA : Mechanism of mitral regurgitation in hypertrophic cardiomyopathy. Mismatch of posterior to anterior leaflet length and mobility. *Circulation* 98 : 856-865, 1998
- 4) Yu EHC, Omran AS, Wigle ED, Williams WG, Siu SC, Rakowski H : Mitral regurgitation in hypertrophic obstructive cardiomyopathy : Relationship to obstruction and relief with myectomy. *J Am Coll Cardiol* 36 : 2219-2225, 2000
- 5) Petrone RK, Klues HG, Panza JA, Peterson EE, Maron BJ : Coexistence of mitral valve prolapse in a consecutive group of 528 patients with hypertrophic cardiomyopathy assessed with echocardiography. *J Am Coll Cardiol* 20 : 55-61, 1992
- 6) Zhu WX, Oh JK, Kopecky SL, Scaff HV, Tajik AJ : Mitral regurgitation due to ruptured chordae tendineae in patients with hypertrophic obstructive cardiomyopathy. *J Am Coll Cardiol* 20 : 242-247, 1992
- 7) Adler O, Kalidindi S, Butt A, Hussain KM : Chordae tendineae rupture resulting in pulmonary edema in a patient with discrete subvalvular aortic stenosis - a case report and literature review. *Angiology* 54 : 613-617, 2003
- 8) Koshino Y, Yasu T, Ishida T, Funayama H, Sugawara Y, Kubo N, Saito M : Acute mitral regurgitation due to ruptured chordae tendineae in a patient with hypertrophic obstructive cardiomyopathy : a case report. *J Cardiol* 47 : 153-158, 2006
- 9) Araujo AQ, Azeredo WV, Arteaga E, Mady C : Total relief of severe left ventricular outflow obstruction after spontaneous rupture of chordae tendineae in a patient with hypertrophic cardiomyopathy. *Heart* 91 : e35, 2005
- 10) Morris AL, Ibrahim M : Hypertrophic obstructive cardiomyopathy complicated by ruptured chordae tendineae to the posterior mitral leaflet and severe congestive heart failure. *Can J Cardiol* 25 : e259-e260, 2009

(2011. 3. 9 received ; 2011. 4. 6 accepted)
